

Role of Negative Pressure Wound Therapy in the Management of Complex Wounds of Lower Limb

Authors;

Milind Chauhan¹, Soniya Chauhan², Nimmy Krishnan³, Rem Kumar Rai⁴, Shreyash Chaudhary⁵

¹All India Institute of Medical Sciences, Jodhpur, <https://orcid.org/0000-0002-8444-6813>

²All India Institute of Medical Sciences, Jodhpur, <https://orcid.org/0009-0007-1446-0568>

³Department of General Surgery, Sree Narayana Institute of Medical Sciences, <https://orcid.org/0000-0002-4792-2462>

⁴Department of Orthopaedics, Tikapur Hospital, Kailali

⁵Department of Paediatric Orthopaedics, SRCC Childrens Hospital, Mumbai

Corresponding Author:

Milind Chauhan

All India Institute of Medical Sciences, Jodhpur, <https://orcid.org/0000-0002-8444-6813>

Article Received: 10-February-2024, Revised: 01-March-2024, Accepted: 20-March-2024

ABSTRACT:

Background: Complex wounds are characterized by extensive loss of skin and soft tissue, often exposing tendons, bones, or implants, and are classified based on criteria such as chronicity, infection, compromised tissue viability, and association with systemic pathologies. Treatment traditionally involved moist gauze therapy but has evolved with the introduction of Vacuum Assisted Closure (VAC) or Negative Pressure Wound Therapy (NPWT), offering controlled sub-atmospheric pressure to enhance wound healing by removing excess fluid, promoting circulation, and converting open wounds into controlled, closed ones. **Methodology:** The study, conducted at the Government Institute of Medical Sciences in Greater NOIDA from August 2019 to March 2021, investigated the effectiveness of Negative Pressure Wound Therapy (NPWT) in managing complex lower limb wounds. Involving 42 patients with exposed wounds and implants, the research applied NPWT using a vacuum pump and recorded dimensions at presentation, patient response, and the time taken for healthy granulation tissue formation. The NPWT dressing system included a polyurethane pack, vacuum pump, canister, and tubes, while microbiological examination and surgical procedures were performed for comprehensive wound management. **Results:** Among the 42 patients, the majority (59.5%) were in the 46-55 age group, with 33.3% in the 35-45 age group and 7.1% in the 25-35 age group. The predominant aetiologies included eight cases of necrotising fasciitis, six traumatic ulcers, and five cellulitis cases. Patients with diabetes mellitus comprised 38% of cases, and the mean wound area significantly decreased from initiation (159.57 mm) to completion (114.5 mm) of NPWT. Wound scoring also significantly improved, and closure was achieved in 52.4% of patients with split-thickness skin grafting. Bacterial clearance notably improved with NPWT, reducing the contamination rate from 98% to 57.1%. The mean duration of hospital stay was 35.35 days, with an average cost of 44091 INR. The study had limitations, such as the sample size, suggesting the need for larger randomized controlled trials for further insights. **Conclusion:** NPWT is highly effective in managing complex wounds, promoting improved microcirculation, rapid formation of healthy granulation tissue, reducing the need for frequent debridement and early wound cover. The study also demonstrates the efficacy of NPWT in promoting healing by secondary intention in complex lower limb wounds, and despite the high cost of dressing, the overall reduction in dressing frequency, debridement's, and hospital stay results in a reduction in the ultimate financial burden.

Keywords: Complex wound, Negative Pressure Wound Therapy, Vacuum Assisted Closure (VAC), Wound dressings

INTRODUCTION:

A complex wound is one with extensive loss of skin and soft tissue with exposure of underlying tendons, bones and implants¹. One or more of the following conditions

must be present for a wound to be categorised as a complex type².

1. Extensive loss of the integument is an important criterion. Chronic wounds are defined as wounds that have not healed expontaneously in three

months and usually have a common pattern of the complexity¹.

2. Infection is frequently present as a complication in chronic wounds and in itself may be the cause of the problem that resulted in tissue loss, as happens in aggressive infections like Fournier's gangrene.
3. Compromised viability of superficial tissues, clear necrosis, or signs of circulation impairment either localised or more extensive, usually in the limbs, leading to extensive loss of substance.
4. Association with systemic pathologies that impair normal healing causing wounds to heal with simple care and requiring special attention. Feet ulcers in diabetic patients and many forms of Vasculitis are common examples.

Each patient with complex wounds usually manifests multiple risk factors for their development. The clinical signs of Complex wounds include non-viable wound tissue (slough and/or necrosis), lack of healthy granulation, no reduction in wound size over time, recurrent wound breakdown. Complex wounds are a growing medical problem across all nations and have always presented a challenge to both the surgeons and patients in operative management, long-term care, cosmetic outcome, and effects on lifestyle, self-image, general health, aging population, increasing prevalence of type II diabetes mellitus along with increasing rates of obesity, all contribute to the rapid incidence of complex wounds.

The treatment of complex wounds is an ancient area of specialisation in medical practice, with a long and eventful clinical history that traces its origins to ancient Egypt and Greece. The Ebers Papyrus, circa BC³ details the use of lint, animal grease, and honey as topical treatment for wounds. The lint provided a fibrous base that promoted wound site closure, the animal grease provided a barrier to environmental pathogens, and the honey served as an antibiotic agent. In modern era these wounds are conventionally managed by standard moist gauze therapy, at least two times a day, saturated in either 0.9% saline solution, 0.2% nitrofurazone (Furacine R), 1% Acetic acid solution or 2% sodium hypochlorite (EUSol) after debridement, which require frequent inspections and changes increasing the chances of bacterial proliferation and further complications³. There are various means of wound healing promoting methods. In past two decades there have been significant advances in complex wound management combines with better understanding of the mechanisms of wound healing and have led to the development of various modalities to aid wound healing⁴. One of the most significant breakthroughs in past few decades was the introduction of Vacuum Assisted Closure (VAC), may also be known as Negative Pressure Wound Therapy (NPWT).

In 1989, Chariker et al. popularised the technique 'Chariker-Jeter technique', using NPWT on cutaneous fistulae over abdomen covering with moist gauze with flat drain covered with occlusive dressing and connecting to pressure of -60 to -80 mmHg⁵. In the early 1990's, Argenta and Morykwas confronted a large number of complex wounds and endeavoured to develop a better method of treatment^{6,7}. They targeted a way to distribute suction to wounds to help draw the edges together and designed several prototypes that facilitated wound healing. The one that has had substantial clinical success consists of open-pore polyurethane foam that is placed in the wound, covered by a semi-occlusive dressing, and connected by a tube to a vacuum source, a method called Negative Pressure Wound Therapy (NPWT). The basic concept of this method is removal of blood and serous collection from the wound site by the application of negative pressure. The therapy involves the controlled application of sub-atmospheric pressure to the local wound environment, using a sealed wound dressing connected to a vacuum pump, turning an open wound into a controlled, closed wound while removing excess fluid from the wound bed to enhance circulation and remove wound fluids⁸⁻¹⁰. This is done by applying a piece of polyurethane foam and a drain over the wound surface debridement and is covered over by a semi-permeable plastic adherent membrane securing it to skin margin and the drain is given connection to a vacuum creating unit. The plastic membrane foams like a barrier preventing the contamination from outside environment and the foam helps to distribute the negative pressure uniformly over the entire wound surface area preventing the chance of necrosis at a single site due to high pressure at single site. In this study we attempt and analyse effectiveness and role of NPWT in management of complex wounds of lower limb.

AIMS AND OBJECTIVE:

Aim of this prospective study was to evaluate the effectiveness of negative pressure wound therapy in the management of complex wounds of lower limbs, resulting from various aetiologies on the basis of type and induration of granulation tissue formed in the wounds, time taken from the starting point of therapy to the formation of healthy granulation tissue, the amount of wound contraction achieved, amount of reduction in wound discharge, and complications of procedure.

MATERIALS AND METHODS:

The study, conducted at the Government Institute of Medical Sciences in Greater NOIDA from August 2019 to March 2021, aimed to investigate the effectiveness of Negative Pressure Wound Therapy (NPWT) in managing complex lower limb wounds. The research involved 42 patients, irrespective of gender, presenting

with exposed wounds and implants, accompanied by thick and purulent discharge on the lower limbs. Exclusions were made for patients unwilling to participate, those with graftable or malignant wounds, wounds related to osteomyelitis, or those with exposed vessels.

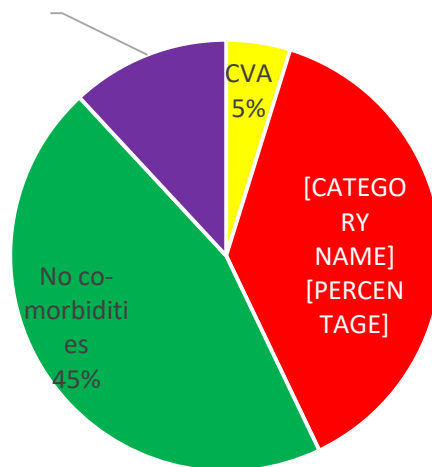
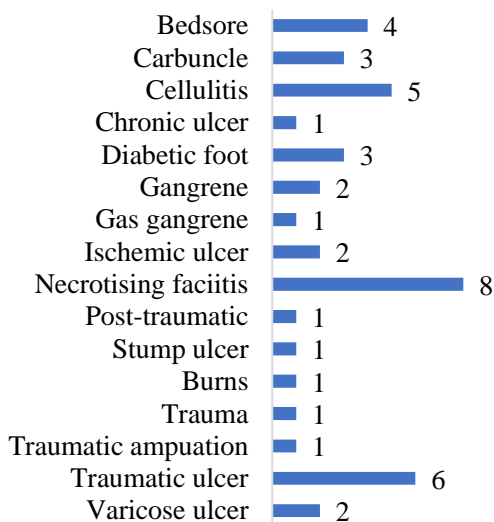
Upon obtaining approval from the Institutional Research and Ethical Committee and securing written informed consent from the patients, a thorough examination of the complex lower limb wounds was conducted. This involved a detailed history, subjective and objective analysis, and an evaluation of conditions leading to the illness. NPWT was applied using a vacuum pump, maintaining a controlled sub-atmospheric pressure through a sealed wound dressing. The wounds' dimensions were recorded at the time of presentation, and patients were assessed for their response to NPWT, receiving additional support in terms of adequate nutrition, fluids, and antibiotics tailored to individual requirements. Follow-ups were conducted at regular intervals, and the time taken from the initiation of NPWT to the formation of healthy granulation tissues enabling closure was recorded.

The NPWT dressing system used in the study comprised a polyurethane dressing pack, a vacuum pump set at negative pressure, a canister, and connecting tubes between the wound dressing and the vacuum pump. Microbiological examination involved the collection of three to four culture swabs from different wound sites. Surgical debridement, irrigation, and cleansing of the wound were performed under spinal anaesthesia, with subsequent application of a sterile, open-cell

polyurethane foam dressing and a fenestrated evacuation tube. The dressing was connected to a computer-controlled vacuum pump with a fluid collection canister. The site was sealed with an adhesive drape to ensure an air-tight seal, and dressings were changed every 48 hours or earlier based on the collection and infectivity of the wound. Controlled negative pressure was uniformly applied, with adjustments based on the type of wound and individual requirements. The pressure mode was set to continuous for the first 48 hours and then modified as per the needs of each case. The study aimed to evaluate the efficacy of NPWT in managing complex lower limb wounds and recorded various parameters to assess the therapy's impact on wound healing.

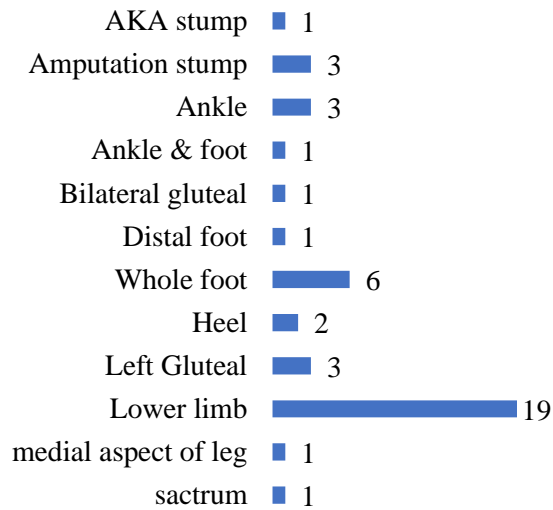
OBSERVATIONS AND RESULTS:

Out of 42 patients, majority i.e., 25 (59.5%) belonged to 46-55 age group interval whereas 14 (33.3%) were in 35-45 age group interval and least i.e., three (7.1%) patients were in 25-35 age group interval. Out of 42 patients, eight had necrotising fasciitis as the predominant aetiology, six patients had traumatic ulcers and five patients had cellulitis as their primary aetiology. Rest patients were admitted with various other aetiologies like bed sores, carbuncle, diabetic foot ulcers etc. out of 42 patients, 19 (45%) patients had no known co-morbidities, whereas 16 (38%) patients were known cases of diabetes mellitus. Rest five (12%) patients were known case of peripheral artery disease, and two (4.8%) patients were known cases of cerebrovascular accidents.



(Figure 1: Frequencies of complex wounds with aetiologies) (Figure 2: Frequencies of co-morbidities)

Out of 42 patients, 19 (45.2) patients had complex ulcers over lower limbs, seven (14.3%) patients had ulcers over foot and distal foot and five of those were known diabetics.



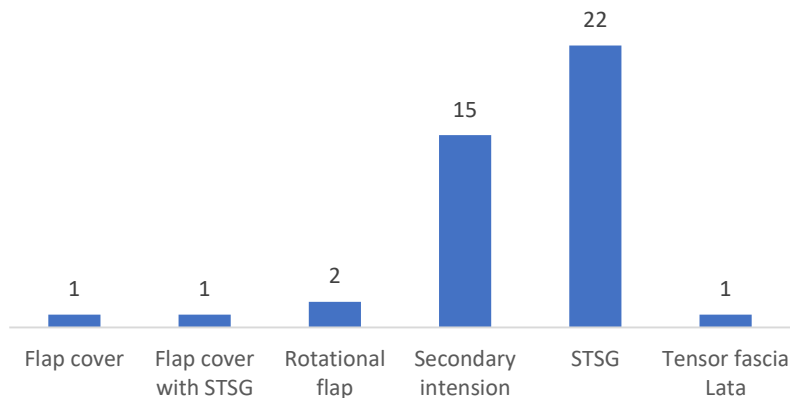
(Figure 3: Ulcer locations)

Wound area on initiation of wound therapy and termination of therapy was calculated and compared on T test which showed a mean of 159.57 mm with a standard deviation of 138.52 at the starting of therapy and final wound area showed a mean of 114.5 mm with a standard deviation of 122.7 and t-value of 7.9 was found to be significant ($p < 0.001$). Wound scoring was compared on T test showing mean of 22.43 and standard deviation of 4.71 during initiation of therapy and final wound area showed a mean of 7.31 with a standard deviation of 3.09 and t-value of 27.61 was found to be significant ($p < 0.001$).

		N	Mean	SD	t-value	p-value
Pair 1	Initial wound area	42	159.57	138.52	7.9	<0.001
	Final wound area	42	114.50	122.17		
Pair 2	Initial wound score	42	22.43	4.71	27.61	<0.001
	Final wound score	42	7.31	3.09		

(Table 1: Wound areas and wound scores)

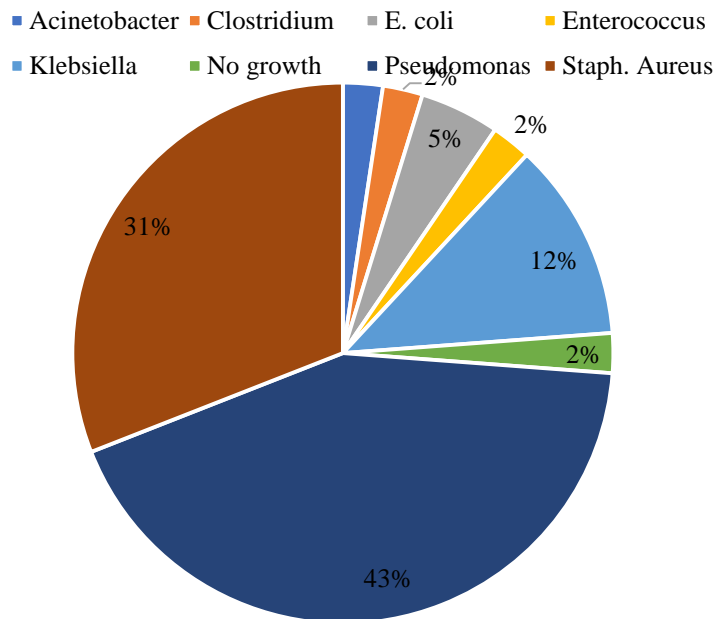
We were able to achieve closure by split thickness skin grafting (STSG) in 22 (52.4%) patients and healing by secondary intention in 15 (35%) patients owing to the smaller size of wounds. Two (4.8%) patients required rotation flap for final closure whereas one (2.4%) patient required combination of STSG and local flap cover and one (2.4%) more patient with gluteal region defect needed combination of tensor fascia lata flap and STSG.



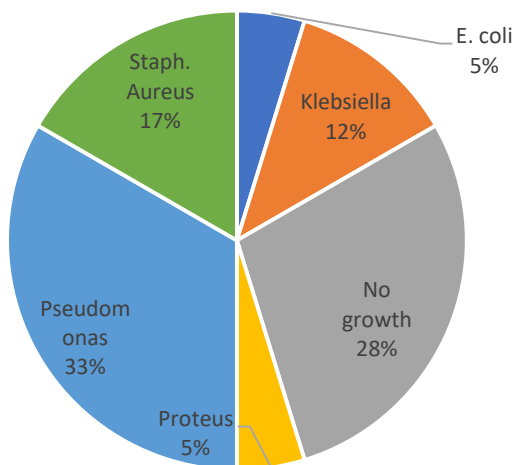
(Figure 4: Modes of wound closure)

A significant improvement was observed on serial cultures in bacterial clearance of wound with use of NPWT with the initial cultures showing a contamination rate as high as 98% with only one culture showing no growth out of 42 cases evaluated. Subsequent second culture after starting the patient on NPWT showed improvement with 12 (28.6%) out of 42

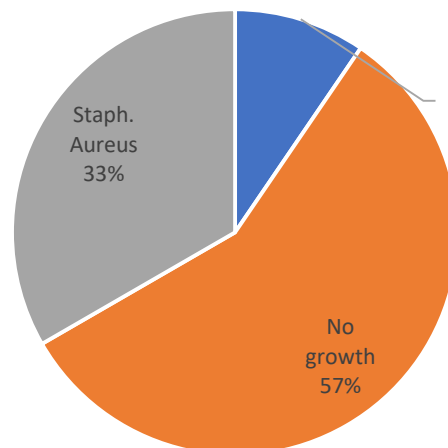
cultures showing no growth. On subsequent cultures there were 24 (57.1%) out of 42 cultures evaluated had no growth, which was a significant improvement over the initial culture before starting NPWT. *Pseudomonas aeruginosa* (42% of all cultures on initial culture) was the commonest organism involved with contamination of these wounds.



(Figure 5: Wound swab culture 1)



(Figure 5: Wound swab culture 2)



(Figure 5: Wound swab culture 3)

	Minimum	Maximum	Mean	SD
Age (years)	26	56	46.98	7.003
Initial wound area	10	560	159.57	138.518
Final wound area	3	512	114.50	122.168
Number of debridement's	1	8	3.05	1.860
Number of dressings	4	30	11.45	5.415
Initial wound score	15	30	22.43	4.712
Final wound score	1	13	7.31	3.088
VAS for pain	2	6	3.98	0.924
Average drain (ml/day)	30	173	96.30	29.423
Duration for closure	7	56	23.05	11.070
Duration of hospitalisation	15	80	35.36	14.683
Cost per dressing (INR)	3850	3850	36850	0
Total cost (INR)	39,100	210,000	97452	42622.772

(Table 2: Descriptive statistical analysis)

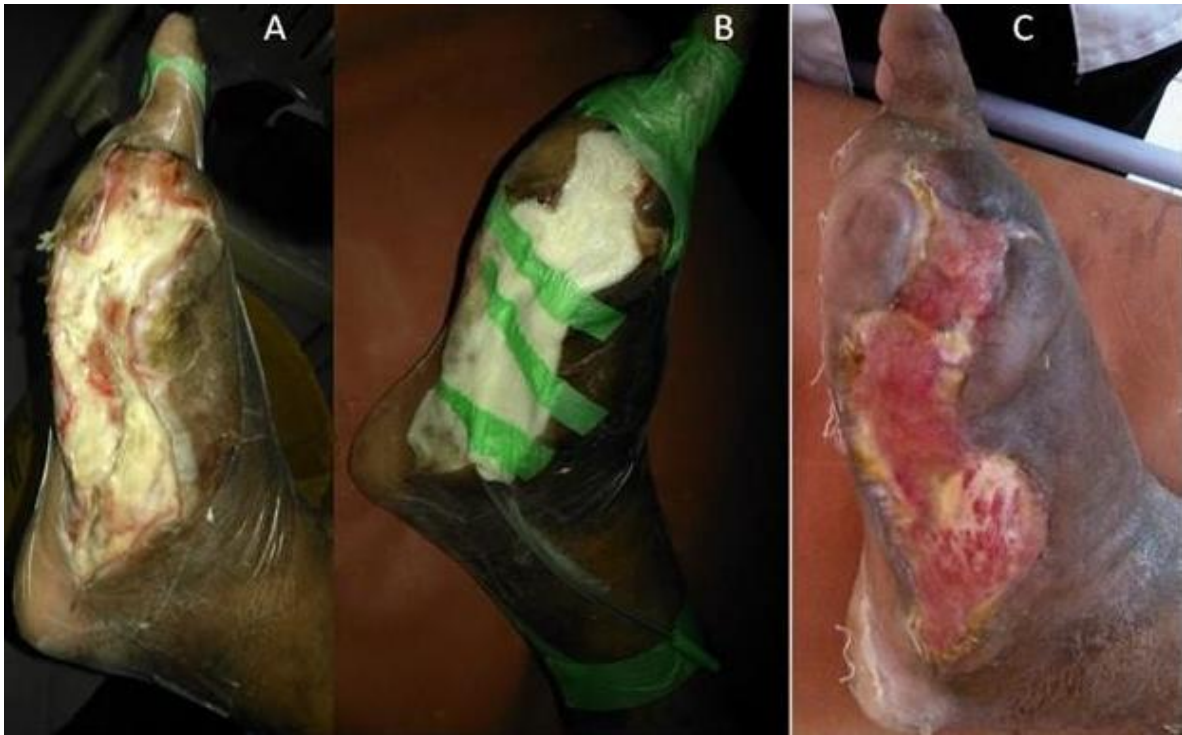DISCUSSION:

Wound healing is a complex interdependent and intricate process involving many cellular interactions, including release of biochemical mediators, changes in the micro-environment of wound base, changes in the extracellular matrix resulting in structural and functional restoration of the wound¹¹. Locally acting growth factors influence wound healing in the events of angiogenesis, extracellular matrix formation, neutrophils, macrophages, and fibroblasts migration increasing collagen and protein production thereby enhancing the process of wound healing¹². Any disturbance in this mechanism will delay in healing and lead to formation of chronic non-healing wounds. Application of sub-atmospheric pressure decreases the bacterial colonisation over the wound and increases blood flow¹³. Increase in oxygenated blood flow to the demand tissues increases the wound resistance to the infection¹⁴. Increased oxygenated blood flow to the wound healing promotes the oxidative burst in neutrophils and thereby promoting microbe-killing and preventing infection¹⁵. NPWT decreases interstitial oedema and increases capillary blood flow, promotes granulation tissue formation, and produces a traction force thereby decreases wound surface area and increases the mitoticity in cells around the area¹⁶. In a multi-centric randomised trial by Blume et al. in 169 patients by vacuum therapy it showed that 43.2% patients treated with NPWT achieved complete closure of ulcer in 56 days and granulation tissue formation in 76 to 100 percent cases¹⁷.

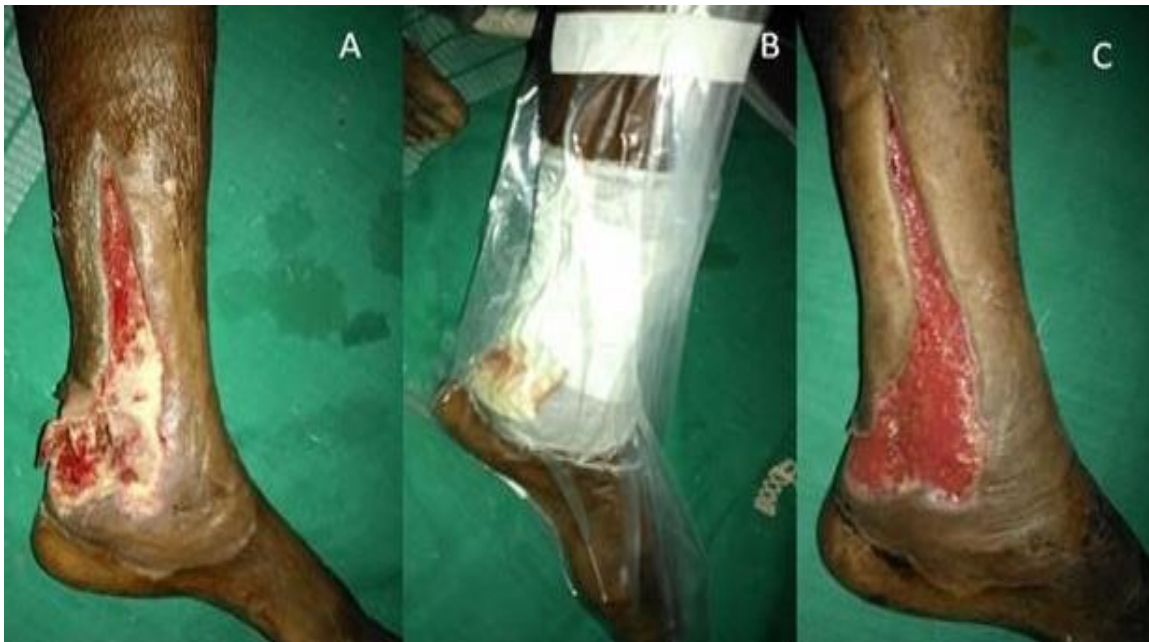In a prospective randomised study by Moues et al. in 29 patients with NPWT there was rapid decrease in wound surface area and enhanced granulation tissue formation¹⁸. In a case-control study by Ali et al. in 56 patients with VAC and conventional dressings it was observed that 44.4% cases with NPWT had no discharge by fourth week and 100% patients developed granulation tissue. *Pseudomonas aeruginosa* was the predominant growth in 39.3% cultures and *Acinetobacter baumannii* in 14.3% cultures, whereas in about 81.8% patients with NPWT wound closure was achieved in five weeks¹⁹. In a prospective comparative study by Tauro Leo Francis et al. 56 (50%) of 112 patients treated with NPWT, 71.43% ulcer was covered by granulation tissue after tenth day NPWT application and the mean hospital stay was 32.64 days²⁰. Treatment of complex wound has always posed a challenge in management due to variable aetiology and multiple factors associated with wound healing like comorbidities, dressing materials etc. In this prospective observational study patients from variable age group were included ranging from 25 to 55 years of age and a median of 40 years with maximum frequency observed in the age group interval of 46-55 years. Out of 42 cases, eight (19%) patients had necrotising fasciitis as the

predominant aetiology, six (14.3%) patients had traumatic ulcers and five (11.9%) patients had cellulitis. Out of 42 patients, 19 (45%) patients had no known comorbidities whereas 16 (38%) patients were known diabetics. Five (12%) patients had peripheral arterial disease and two (4.8%) patients had old CVA. A total of 19 (45.2%) patients had complex ulcers over lower limb, seven (14.3%) patients had ulcers over distal foot five out of which were diabetics. Wound area on initiation and termination of NPWT was calculated and compared on T test which showed a mean of 159.57 mm with a standard deviation of 138.52 at initiation, whereas final wound area was suggestive of a mean of 114.5 mm with a standard deviation of 122.7 and t-value was found to be significant ($p < 0.001$). Wound scores compared on T test inferred a mean of 22.43 with a standard deviation of 4.71 at initiation of therapy, whereas a mean of 7.31 with a standard deviation of 3.09 at termination of NPWT and t-value was found to be significant as 27.61 ($p < 0.001$).

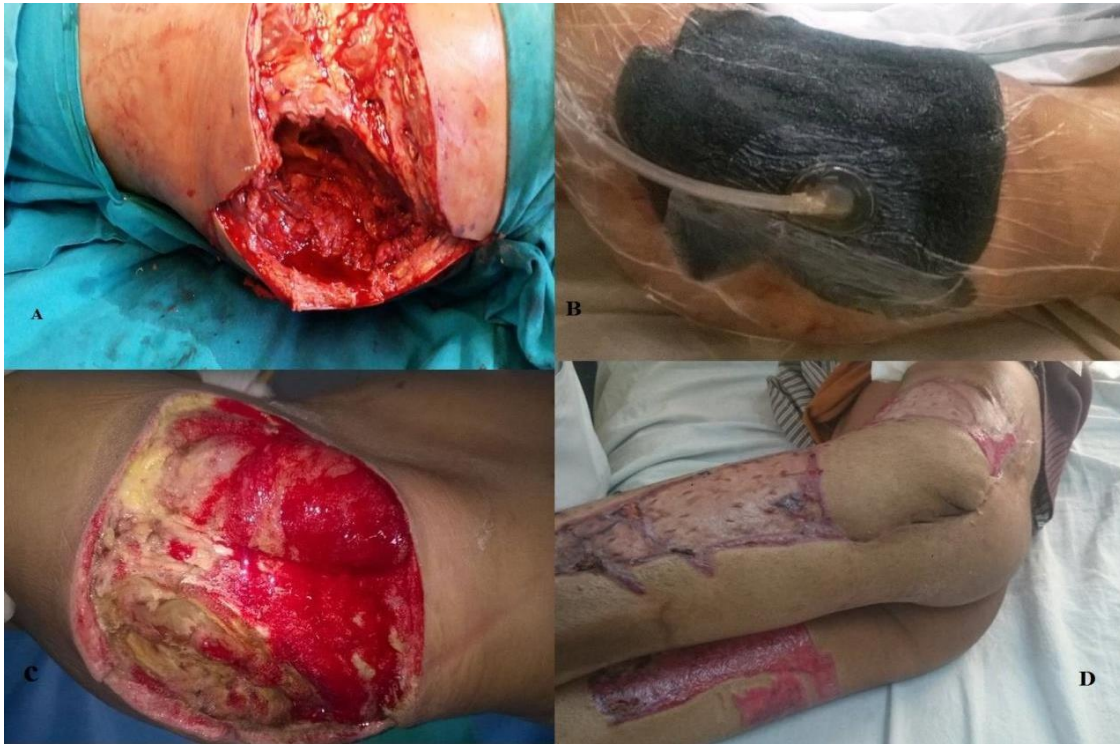Time taken for granulation tissue formation and subsequent closure was 7 to 15 days with a mean of 23.05 and standard deviation of 11.07. to achieve complete closure of wounds, patients required a minimum of four to maximum of eight debridement's with a mean of 3.05. Number of dressings for each patient varied from four to maximum 30 with a mean of 11.45 and stand deviation of 5.415. The average drain volume was from 30 ml per day to a maximum volume of 173 ml per day with a mean of 96.31 ml and standard deviation of 29.77. We were able to achieve closure by STSG in 22 (52.4%) patients and healing by secondary intention in 15 (35%) patients owing to small size of the wounds. We have observed a significant improvement in the bacterial clearance of wound with use of NPWT with initial cultures showing a contamination rate as high as 98% with only one culture showing no growth. Subsequently, second culture after starting NPWT showed improvement with 12 (28.6%) cultures showing no growth, whereas 24 (57.1%) culture had no growth on third culture showing significant improvement over the initial culture before stating NPWT. *Pseudomonas aeruginosa* was the commonest grown micro-organism over 42% in first culture and 33.3% in second culture. The mean duration of hospital stay was 35.35 days with average cost involved in management of complex wounds with NPWT was 44091 INR per with a standard deviation of 20850 INR. There were no complications like of skin maceration, bleeding, and failure of vacuum during our study. Limitations were present like sample size, even though statistical analysis was done, but further randomised control study with larger sample size comparison might reveal variations which could not be done.



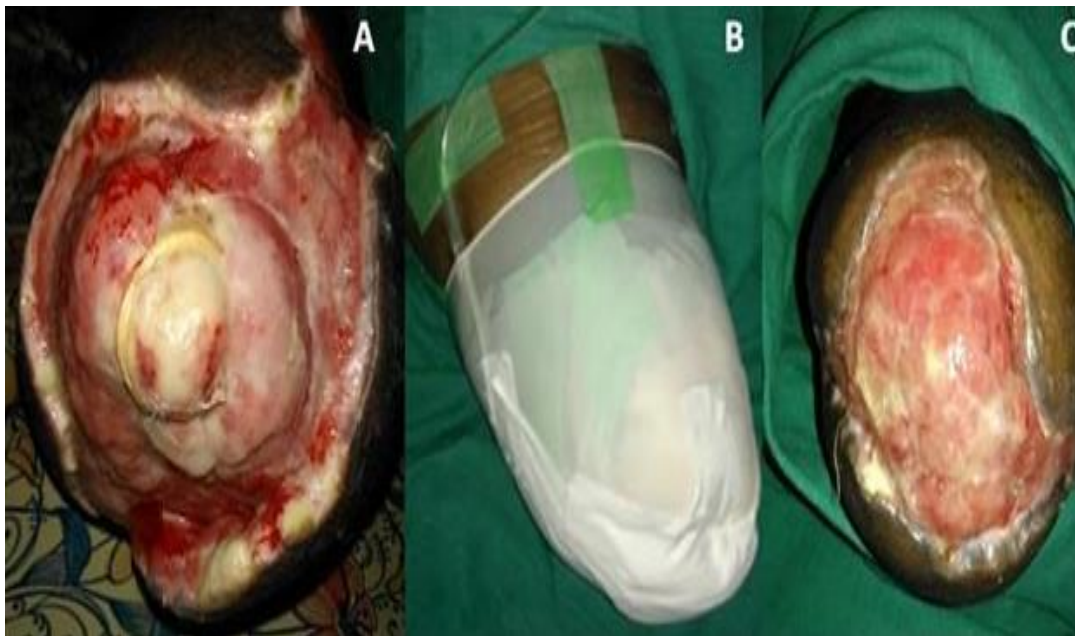(Image 1; A: Open diabetic foot wound after debridement but before NPWT application. B: NPWT application. C: Wound healing response after 17 sittings of NPWT. NPWT*: Negative Pressure Wound Therapy)



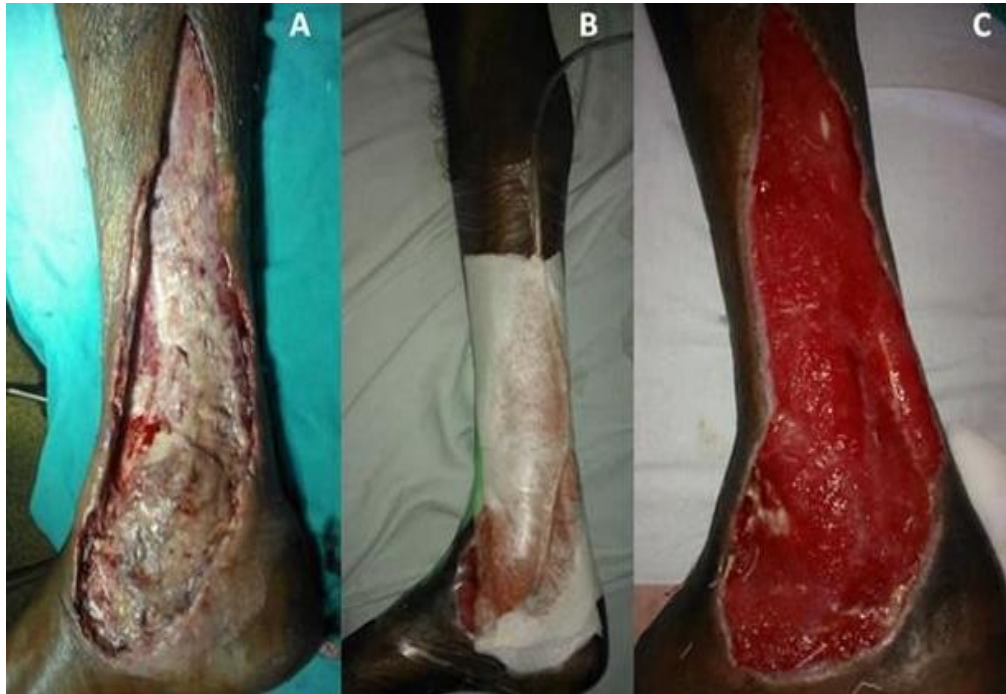(Image 2; A: Necrotising fasciitis wound over left lower limb. B: NPWT application. C: Wound healing response after 8 sittings of NPWT)



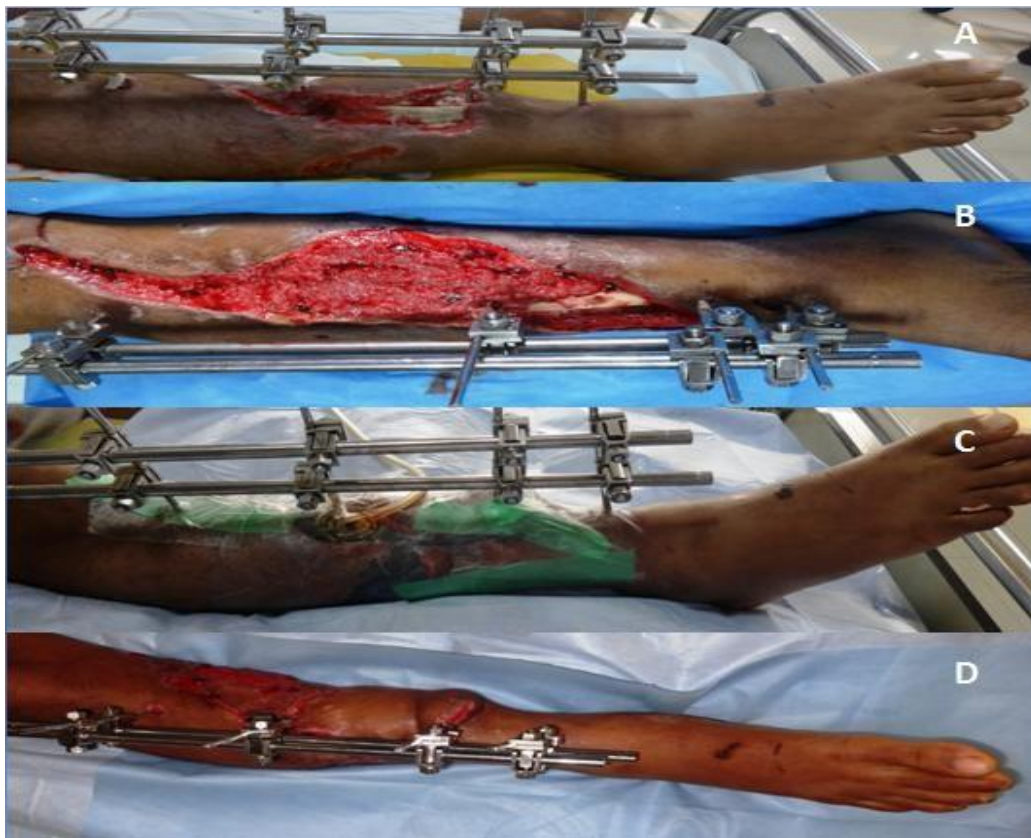(Image 3; A: Gas gangrene of left gluteal region with exposed joint capsule. B: NPWT application. C: Development of pink granulation tissue after 30 sittings of NPWT. D: Final closure with tensor fascia Lata flap and SSG)



(Image 4; A: Right above knee amputation (AKA) for diabetic foot with exposed bone. B: NPWT application. C: Wound healing response after 17 sittings of NPWT)



(Image 5; A: Necrotising fasciitis wound over left lower limb. B: NPWT application post-debridement. C: Wound healing response after 17 sittings of NPWT)



(Image 6; A: Complex wound over right lower limb with comminuted tibia fracture. B: Wound after serial debridement's. C: NPWT application post-debridement. D: Final closure of wound with STSG and local Flap)

CONCLUSION:

The negative pressure wound therapy is highly effective in managing complex wound on basis of improved

microcirculation and rapid healthy granulation tissue formation reducing need of frequent debridement and early wound cover and significant reduction in hospital

stay duration. This study also proves that complex wounds of lower limb heal by secondary intention with use of NPWT. *Pseudomonas aeruginosa* is the commonest organism to colonise complex wounds. NPWT is effective in rapid clearance of infection from wound site. Despite high cost of dressing since there is overall reduction in frequency of dressing and debridement's along with reduced hospital stay thereby reducing ultimate financial burden.

REFERENCES:

1. Harding KG, Morris HL, Patel GK. Science, Medicine, and the future: healing chronic wounds. *BMJ*. 2002; 324:160-3.
2. Ferreira MC, Tuma Jr. P, Carvalho VF, Kamamoto F. Complex wounds. *Clinics*. 2006;61(6):571-8.
3. Ovington LG "The evolution of wound management: ancient origins and advances of the past 20 years". Oct 2002; (10): 652.
4. Chantal M. "Topical Negative pressure in wound care effectiveness and guidelines for clinical application": chapter iii, page 40.
5. Chariker M, Jeter K, Tittle T. Effective management of incisional and cutaneous fistulae with closed suction wound drainage. *Contemp Surg* 1989; 34:59-63.
6. Argenta LC, Morykwas MJ. Vacuum-assisted closure: a new method for wound control and treatment: clinical experience. *Ann Plast Surg* 1997; 38:563-76.
7. Morykwas MJ, Argenta LC, Shelton-Brown EI, Mc Guirt W. Vacuum-assisted closure: a new method for wound control and treatment: animal studies and basic foundation. *Ann Plast Surg* 1997; 38:553-62.
8. Lillis, Karin. "Effective wound care requires look at total patient picture". *Healthcare Purchasing News*. 2003; 27 (1): 32.
9. McGregor, Dendukuri, N. "The clinical effectiveness of negative pressure wound therapy: a systematic review". *Journal of Wound Care*. Nov 2010; 19 (11): 490-5.
10. Baxter, Helena; Ballard, Kate "Vacuum-Assisted Closure". *Nursing Times*. 2001; 97 (35): Page 51-2.
11. R.A.F. Clarke and P.M. Henson, Eds., *The Molecular and Cellular Biology of Wound Repair*, Plenum Press, New York, NY, USA, 1988.
12. D. J. Whitby and M. W. J. Ferguson, "Immunohistological studies of the extracellular matrix and soluble growth factors in fetal and adult wound healing," in *Fetal Wound Healing*, N. S. Adzick and M.T. Longaker, Eds., pp.161-177, Elsevier Science, New York, NY, USA, 1992.
13. M. J. Morykwas and L. C. Argenta, "Vacuum-assisted closure: a new method for wound control and treatment: clinical experience," *Annals of Plastic Surgery*, vol.38, no.6, pp.563-577,1997.
14. T. K. Hunt, "The physiology of wound healing," *Annals of Emergency Medicine*, vol. 17, no. 12, pp. 1265-1273, 1988.
15. T. J. Ryan, "Microcirculation in psoriasis: blood vessels, lymphatics and tissue fluid," *Pharmacology and Therapeutics*, vol.10, no.1, pp.27-64,1980.
16. Leininger BE, Rasmussen TE, Smith DL, Jenkins DH, Coppola C. Experience with wound V AC and delayed primary closure of contaminated soft tissue injuries in Iraq. *J Trauma* 2006; 61:1207-1211.
17. Blume P A, Walters J, Payne W, A yala J, Lantis J. Comparison of negative pressure wound therapy using vacuum-assisted closure with advanced moist wound therapy in the treatment of diabetic foot ulcers: a multicenter randomized controlled trial. *Diabetes Care* 2008; 31:631-6.
18. Mouës CM, van den Bemd GJ, Heule F, Hovius SE. Comparing conventional gauze therapy to vacuum assisted closure wound therapy: a prospective randomised trial. *J Plast Reconstr Aesthet Surg* 2007; 60:672-81.
19. Ali M. Lone, Mohd I. Zaroo, Bashir A. Laway, Nazir A. Pala, Sheikh A. Bashir, Altaf Rasool. Vacuum-assisted closure versus conventional

dressings in the management of diabetic foot ulcers: a prospective case control study *Diabetic Foot & Ankle* 2014,5:23345.

20. Tauro LF, Ravikrishnan J, Satish Rao B S, Shenoy H D, Shetty S R, Menezes LT. A comparative study of the efficacy of topical negative pressure moist dressings and conventional moist dressings in chronic wounds. *Indian J Plast Surg* 2007; 40:133-40.