

Case Report

A Case report of primary isolated hydatid cyst of the breast

Authors:

1. Dr. Hasan Khalaf , 2. Dr. Basim Almothafar
Department of General surgery in ALSader hospital Iraq

Correspondence Author:

Dr. Hasan Khalaf
Department of General surgery in ALSader hospital Iraq

Article Received 19-09-2020, Accepted 15-10-2020 , Published 20-10-2020

ABSTRACT:

Human Echinococcosis is a zoonotic disease (a disease that is transmitted to humans from animals) that is caused by parasites, namely tapeworms of the genus Echinococcus. The diagnosis of hydatid disease is based on clinical assessment, serology, ultrasonography (USG). Hydatid cysts may be found in almost any part of the body but are most often found in the liver (60 %) and lungs (30 %) [1]. Breast involvement is rare accounting for only 0.27 % of the localization [2]. We report a case of 19 years old female who presented as a case of breast lump, which was later confirmed to be a case of hydatid cyst of the breast. Hydatid disease is rare in this part of the country, and hydatid disease of the breast is even rare.

Keywords: *hydatid cyst, triple assessment and ultra-sound scan*

Case Report:

A 19 years old female presented to the breast clinic with feeling a lump in her left breast for 8 months. The lump was painless and with no nipple discharge. She has no family history, and she is not using Hormonal replacement therapy. She had no history of weight loss. On examination, her right breast and axilla were normal. The left breast with 3*3 cm mobile, painless lump. The lump with well defined boundaries. There were no skin changes in the breast and the nipple. She had no axillary or supraclavicular lymphadenopathy. Full blood count test was normal. Patient was sent for Ultra sound scan that showed signs of single

hydatid cyst of the breast. The decision was made not to perform fine needle aspiration. Chest x-ray and liver scan showed no hydatid cysts. The patient was taken for elective hydatid cyst removal under general anaesthesia. Radical excision of the cyst was performed without immediate intraoperative complication [fig 1].

There was uneventful in-patient recovery stage. She was discharged in good general condition. In her follow up, her wound healed without complications. Histopathological examination confirmed the diagnosis of hydatid cyst of the breast.

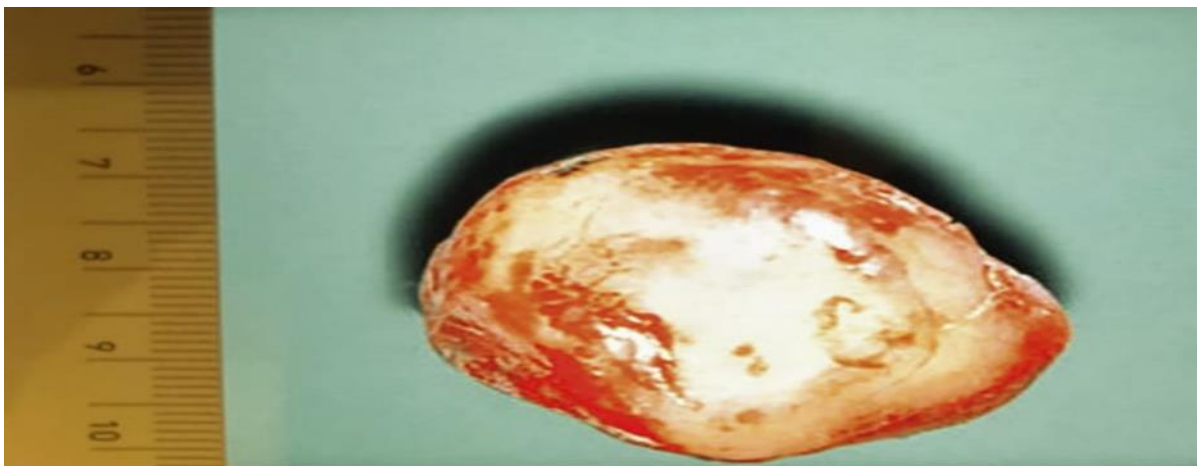

Figure 1 showing the radical excision of the hydatid cyst

DISCUSSION:

Echinococcosis is a parasitic disease caused by infection with tiny tapeworms of the genus *Echinococcus*. Human echinococcosis (hydatidosis, or hydatid disease) is caused by the larval stages of

cestodes (tapeworms) of the genus *Echinococcus*. People usually become infected by accidentally swallowing the tapeworm eggs passed in dog faeces. A human act as an intermediate host in the same way as a sheep, horse [fig2].

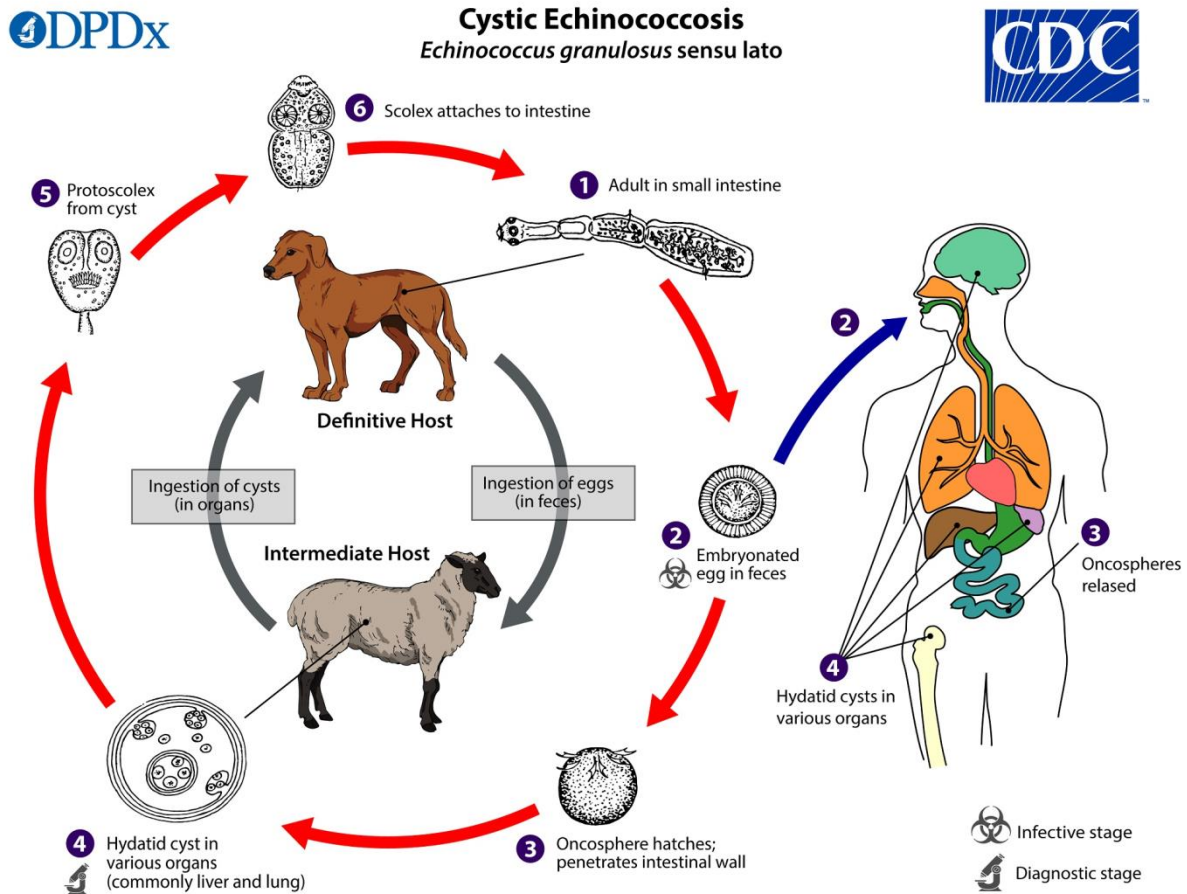


Figure 2 showing the incidental infection of the Human.

Echinococcus granulosus (*sensu lato*) causes cystic echinococcosis and is the form most frequently encountered. Another species, *E. multilocularis*, causes alveolar Echinococcosis, and is becoming increasingly more common. Patients with Echinococcosis often remain asymptomatic until hydatid cysts containing the larval parasites grow large enough to cause discomfort, pain, nausea, and vomiting. The cysts grow over the course of several years before reaching maturity and the rate at which symptoms appear typically depends on the location of the cyst. The cysts are mainly found in the liver and lungs but can also appear in the spleen, kidneys, heart, bone, and central nervous system, including the brain and eyes [3]. Hydatid cyst in the breast is extremely rare [4]. The clinical presentation depends on the size of the breast and the size of the hydatid cyst. Hydatid cyst of breast usually present with a painless, slowly growing lump in the breast of long duration without axillary lymphadenopathy. It affects generally women in the age group of 30-50 years. Due to this clinical presentation and rarity of

this entity in breast it mimics fibroadenoma or fibrocystic disease in younger females and malignancy in older age. In our case also hydatid disease was not suspected, and the ultrasound scan gave high suspicion of the diagnosis [5]. We use triple assessment to assess breast lump. The triple assessment includes breast and axilla examination, ultrasound scan or mammograph and FNAC. In our case presentation, the ultrasound scan showed high evidence of hydatid cyst. There was no need for fine needle aspiration as high risk of anaphylactic shock due to cyst rupture [6]. Histopathological examination confirm diagnosis by identification of hydatid cyst walls and scolices. The treatment of choice of hydatid cyst of breast is complete surgical excision of cyst and its contents without spillage into the surrounding tissue. Preoperative chemotherapy with albendazole may reduce the recurrence of disease. The recurrence rate due to incomplete removal or unidentified cyst has remained between 2% and 25% [7].

CONCLUSION:

A high level of clinical suspicion and following the best triple assessment are required for the diagnosis of hydatid cyst in the breast. Although the isolated hydatid cyst of the breast is rare, we need to keep it in the differential diagnosis of the breast lumps. In our case report, we were able to diagnose the isolated hydatid cyst of the breast using ultrasound scan and avoid unnecessary Fine needle aspiration that could lead to complication.

REFERENCES:

1. Krasniqi et al. Primary hydatid cyst of the gallbladder: a case report. *Journal of Medical Case Reports* 2010, 4:29 <http://www.jmedicalcasereports.com/content/4/1/29>
2. Abi F, Fares F, Khasis D, Bouzidi A (1989) Unusual localization of
3. <https://www.cdc.gov/parasites/echinococcosis/disease.html>

hydatid cyst. *Aproposes of 40 cases. L Chir* 307–312

4. Kapila K, Verma K (1982) cytologic: detection of parasitic disorder. *Acta Cytol* 26:359–362
5. Vega A, Ortega E, Cavada A, Garijo F, 1994. Hydatid cyst of the breast: Mammographic findings. *AJR Am J Roentgenol* 162: 825–826.
6. Russel RCG, Williams NS, Bulstrode CJK (2004) Triple assessment of breast lumps. *Short Practice of Surgery by Bailey of Love*. Arnold Publications 24th Edition, 826
7. Yaqoob N, Kayani N, Shamim MS. Mammary echinococcosis: Two cases and literature review. *J Pak Med Assoc* 2004;54:283-4.