

## Accuracy of Small Biopsy Diagnosis of Ovarian Tumors In Correlation With Histopathology of Oophorectomy Specimens.

### Authors:

Dr. Priyanka Lal J<sup>1</sup>, Dr. Lila Rani Vijayaraghavan<sup>2</sup>, Dr. Geetha Vasu<sup>3</sup>

<sup>1</sup>MD Pathology, Senior Resident, <sup>2</sup>MD Pathology, Professor, <sup>3</sup>MD Pathology, Professor.  
Department of Pathology, Sree Mookambika Medical College, Kulasekharam, Tamil Nadu, India.

### Corresponding Author:

Dr. Priyanka Lal . J

SFS Cyber Gateway Apartments, Tivoli Block, Flat No: 4D, Kazhakkottam, Trivandrum.

Article Received: 26- September -2024, Revised: 16-October-2024, Accepted: 06-November-2024

### **ABSTRACT:**

**Introduction:** Ovarian carcinoma accounts for 3% of all carcinomas in women. Ovarian tumors are difficult to diagnose on the basis of their clinical or gross appearance alone. Timely surgical removal of ovarian tumors, especially for borderline and malignant tumors is the best treatment approach. Therefore, accurate diagnosis of ovarian tumors is of prime importance for better management of the patient. **Aims and objectives:** The aim of our study is to assess the small biopsy diagnosis of ovarian tumors in correlation with corresponding oophorectomy specimen histopathology. **Materials and methods:** This prospective study was conducted among all patients with lesions of ovary which were sent for small biopsy diagnosis and later oophorectomy histopathology diagnosis at the Department of Pathology, Sree Mookambika Institute of Medical sciences. **Observation and Results:** In this study, total of 30 patients were included, with mean age of 42.46±16.71yrs. On assessment, the precision of small biopsy to detect malignant lesions from benign and borderline was found to be 100% with 100% sensitivity and specificity. **Conclusion:** The present study found a significant association in the precision of diagnosis by small biopsy method in neoplasms of ovary in correlation with corresponding oophorectomy specimen histopathology.

**Keywords:** Ovarian neoplasms, Small biopsy, Histopathology.

### **INTRODUCTION:**

Ovarian carcinoma accounts for 3% of all carcinomas in women. They constitute 25% among all female genital tract neoplasms and is the commonest cause for mortality in women (30%). The risk factors of ovarian cancer are family history, age over 65 years, pelvic inflammatory disease, infertility treatment, hormone replacement therapy, obesity, smoking, endometriosis etc. Ovarian mass can be benign, borderline or malignant. Timely surgical removal, especially for malignant and borderline ones, is a best treatment approach. Therefore, accurate diagnosis of ovarian lesions is of prime importance for better management of the patient.

### **MATERIALS AND METHODS:**

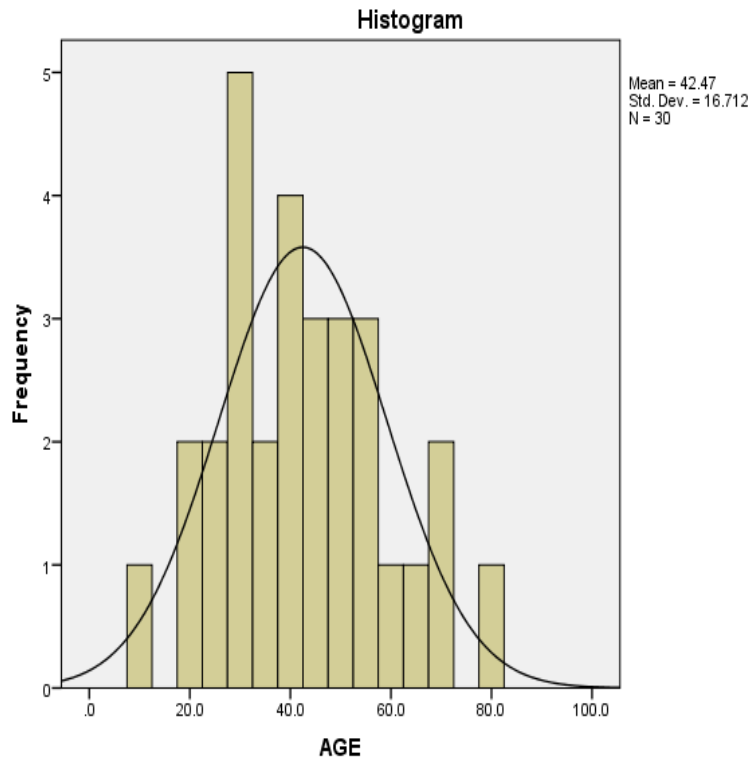
This prospective study was conducted at the Department of Pathology, Sree Mookambika Institute of Medical sciences, Tamil Nadu, India. All cases of ovarian lesions which had both small biopsy and corresponding oophorectomy specimen, received in the Department of Pathology, over a period of one year were taken for this study. A total of 30 cases were received during this study period. All cases were selected for the study as the samples were adequate. The specimens were subjected to routine processing and Hematoxylin & Eosin (H&E) staining.

### **RESULTS:**

A total number of 30 cases over 1 year time period were evaluated. Age of the patients ranged from 42.46±16.71 years.

	N	Minimum	Maximum	Mean	SD
Age in years	30	10.0	79.0	42.46	16.71

Table 1: Mean age of study participants



**Figure 1: Mean age of study participants**

**Table 2: Comparison of small biopsy diagnosis with histopathology diagnosis of oophorectomy specimens.**

		Oophorectomy specimen histopathology findings						Chi-square (p-value)
		Benign		Borderline		Malignant		
		Count	N %	Count	N %	Count	N %	
Small biopsy findings	Benign	10	100.0%	0	0.0%	0	0.0%	60.0 (0.001)**
	Borderline	0	0.0%	14	100.0%	0	0.0%	
	Malignant	0	0.0%	0	0.0%	6	100.0%	

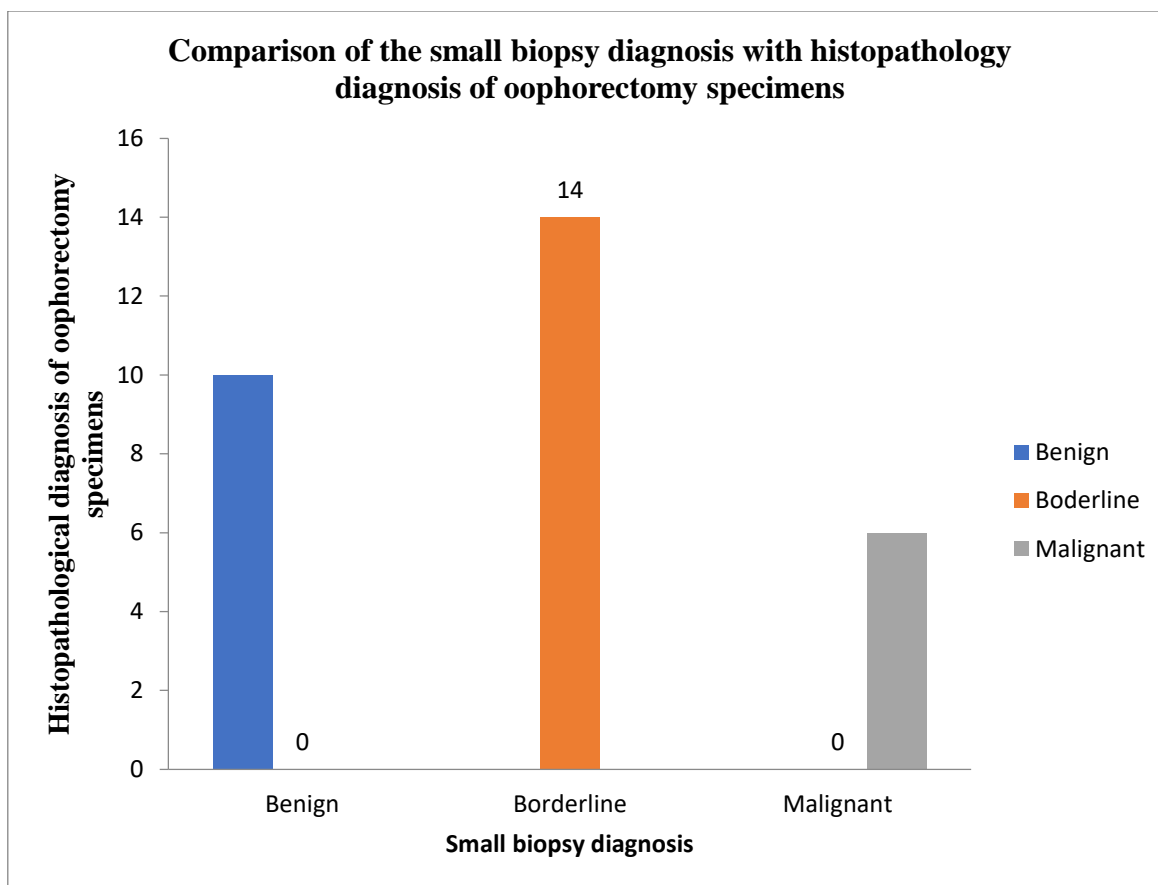


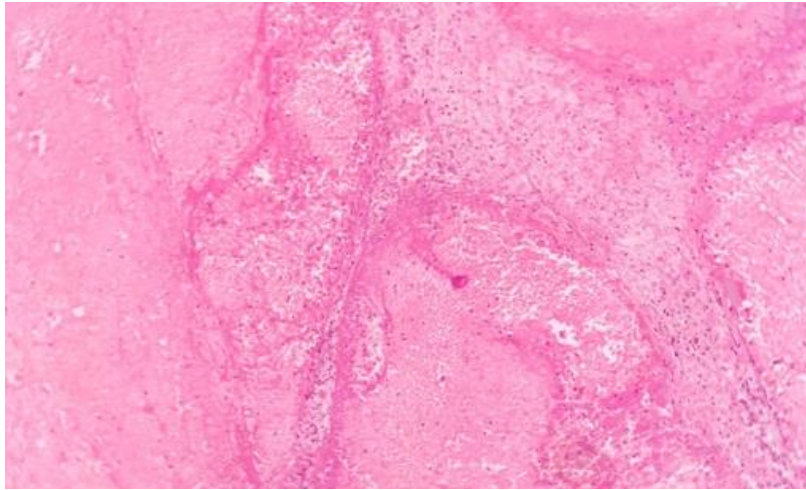
Figure 2 : Showing the comparison of small biopsy diagnosis with histopathology diagnosis of oophorectomy specimens.

Table 3: Diagnostic specifications

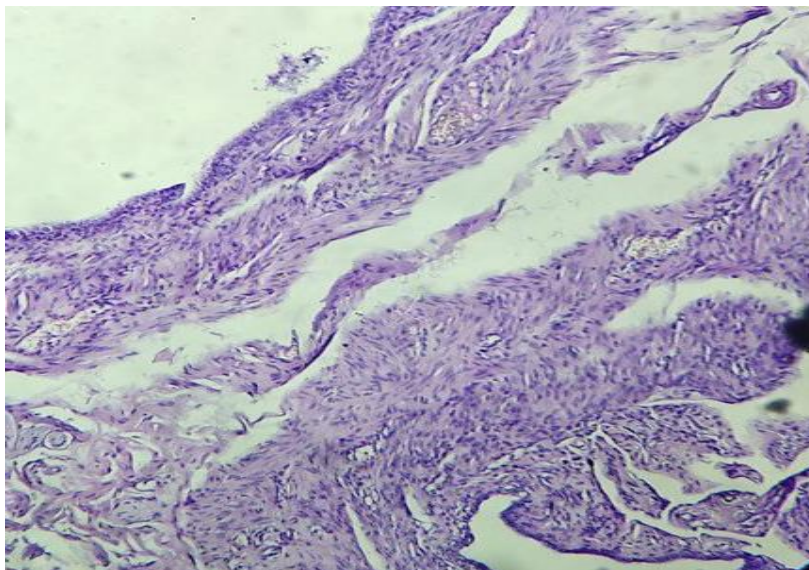
Statistic	Value	95% CI
Sensitivity	100.00%	54.07% to 100.00%
Specificity	100.00%	85.75% to 100.00%
Positive Predictive Value (*)	100.00%	
Negative Predictive Value (*)	100.00%	
Accuracy (*)	100.00%	88.43% to 100.00%

**DISCUSSION:**

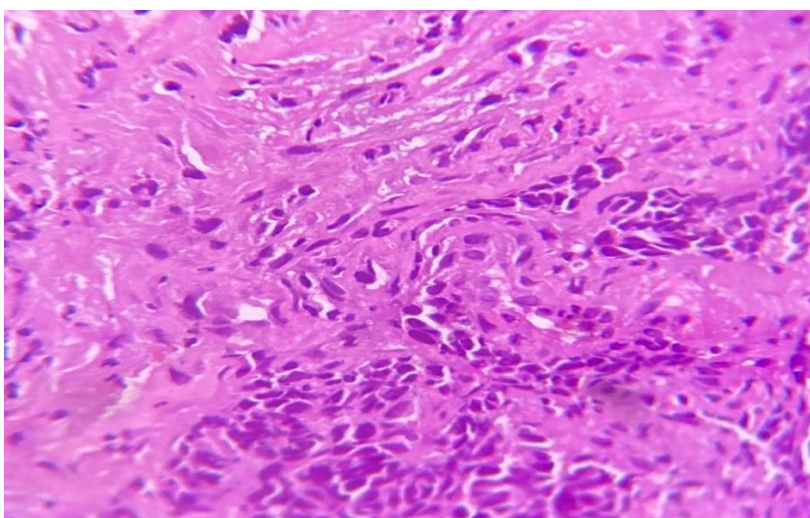
In this study, 30 cases satisfying the inclusion criteria were involved, with mean age of 42.46 ± 16.71yrs. USG abdomen and pelvis done for 29 cases showed the presence of malignant ovarian neoplasm, complex ovarian cyst, adnexal cyst, benign cyst, ovarian torsion and simple ovarian cyst. The various clinical diagnosis was found to be cystic neoplasm, cystic teratoma, ovarian neoplasm, dermoid cyst, malignant neoplasm and torsion.



**Fig 3 : Histopathology of Torsion ovary**



**Fig 4 : Histopathology of Mixed epithelial carcinoma**



**Fig 5: Histopathology of Poorly differentiated adenocarcinoma**

## **CONCLUSION:**

Small biopsy diagnosis is very helpful and very accurate in cases of malignant and benign neoplasms of ovary. However, concerned pathologist who is reporting should be aware that, in borderline ovarian tumors, due to the large size of tumors, solid and cystic components, multi loculations, heterogeneity (focal areas of borderline microscopic foci) and sampling errors decreases the diagnostic accuracy. In this study, in case of ovarian neoplasms, there is marked similarity between small biopsy diagnosis and histopathology diagnosis of corresponding oophorectomy specimens.

## **REFERENCES:**

- 1) Kumar V, Abbas A, Aster J. Ovaries. In: Robbins Basic Pathology. 9th ed. Canada: Saunders Elsevier; 2013. p. 695–700.
- 2) Reid BM, Permuth JB, Sellers TA. Epidemiology of ovarian cancer: a review. *Cancer Biol Med.* 2017;14(1):9–32.
- 3) Maheshwari V, Tyagi SP, Saxena K, Tyagi N, Sharma R, Aziz M, et al. Surface epithelial tumours of the ovary. *Indian J Pathol Microbiol.* 1994;37(1):75–85.
- 4) Kayastha S. Study of ovarian tumours in Nepal Medical College Teaching Hospital. *Nepal Med Coll J.* 2009;11(3):200–2.
- 5) Jha R, Karki S. Histological pattern of ovarian tumors and their age distribution. *Nepal Med Coll J.* 2008;10(2):81–5.
- 6) Pilli GS, Suneeta KP, Dhaded A V, Yenni V V. Ovarian tumours: a study of 282 cases. *J Indian Med Assoc.* 2002;100(7):420,423-424,447.
- 7) Modepalli N, Venugopal SB. Clinicopathological Study of Surface Epithelial Tumours of the Ovary: An Institutional Study. *J Clin Diagn Res.* 2016;10(10):EC01–4.