

## Outcome of the Kerr Anterior Tab Flap in a tertiary care center in western Nepal

### Authors:

Sagun Shrestha<sup>1</sup>, Malika Baidya<sup>2</sup>, Saharaj Siddiqui<sup>3</sup>, Kundan Shah<sup>3</sup>

<sup>1</sup>Department of ENT-HNS, Bheri Hospital, Nepalgunj, Nepal

<sup>2</sup>Paropakar Maternity and Women's Hospital, Thapathali, Kathmandu, Nepal

<sup>3</sup>Intern Doctor, Nepalgunj Medical College, Nepalgunj, Nepal

### Corresponding Author:

Sagun Shrestha, Consultant ENT surgeon, Department of ENT-HNS, Bheri Hospital, Nepalgunj, Nepal

Article Received: 20- September -2024, Revised: 10-October-2024, Accepted: 30-October-2024

### **ABSTRACT:**

**Objective:** This study aimed to evaluate the outcome of myringoplasty using the Kerr flap technique in all cases of tympanic membrane (TM) perforations involving the anterior region as well as noting the concern of hearing gain, Air-Bone gap (AB gap) closure and incidence of complications. **Methods:** This prospective study recruited 118 patients who underwent myringoplasty using the Kerr flap technique between 2021 and 2024. The effects of the surgical treatment were assessed by changes in pre- and postoperative Pure tone Audiogram (PTA) and AB gap data as well as complication rates. **Results:** The patients included in the study had chronic TM perforations, and significant surgical improvements in PTA and AB gap outcomes were observed. The technique of the Kerr flap was effective in achieving success for graft fixation as well as maintaining tension in the anterior segment to effectively close the AB gap with a median of 9.7 decibels (dB). This study showed a high success rate using the method showing only one patient with complication (ear discharge) that was managed conservatively. **Conclusion:** The Kerr flap technique in myringoplasty is efficient in terms of hearing gains and a relatively low complication rate mainly in anterior region TM perforations. Based on the capacity to offer sufficient fixation and tension toward the anterior segment of the graft, it is considered as beneficial and adjustable in otologic surgery for addressing different TM repair concerns.

**Keywords:** *Kerr Anterior, myringoplasty, tympanic membrane*

### **INTRODUCTION:**

Myringoplasty is a surgical procedure whose main purpose is to repair perforations in the TM with the objectives of improving hearing capacity and preventing reinfections. The most common causes of chronic perforations of the TM include chronic otitis media, trauma, as well as previous surgery.<sup>1</sup> If these perforations are not treated, then it can result in severe ear problems such as complete hearing loss, continuous ear discharge and even more dangerous extra and intracranial consequences.<sup>1-4</sup>

Several surgical techniques have been developed for reconstructing the TM, but many are turning to the Kerr flap technique given the outcome.<sup>5</sup> This technique involves developing a tunnel flap of skin in the anterior canal wall, through which an anterior tab of temporalis fascia graft is pulled through.<sup>6</sup> There is optimism about the success of the graft and changes in hearing quality from the application of the Kerr flap technique, making

it a suitable option for repair of the tympanic membrane.<sup>7</sup>

The purpose of this work is to evaluate the outcomes of myringoplasty with the use of the Kerr flap method. The outcomes include assessing graft success rate, measuring hearing gain using pure-tone audiometry, and reporting any adverse event during the follow-up period. By exploring these outcomes, this study expects to contribute to the understanding of the effectiveness of the technique called the Kerr flap in patients presenting with perforations in their tympanic membrane and possible ways of promoting better surgical outcomes among the patient population.<sup>8</sup> The findings will be able to provide clinicians with fundamental pieces of information that they can utilize to determine which surgical approaches seem most appropriate in otologic practice.

**METHODS:**

**Study Design:**

This prospective study was conducted at Bheri Hospital from April 2021 till March 2024. Informed written consent was obtained from all the participants before participating in the research activity.

**Participants:**

The patients included in the research were 118 in number, of both sexes, ranging from 9-60 years old, diagnosed with chronic tympanic membrane perforation using an Otoscope. Patients with TM perforation only in the posterior region of the TM, infected ears or tubes who had previously undergone surgery or had other comorbidities were excluded from the study. Patients were selected from the outpatient clinic, and the medical records were carefully screened to identify patients who met with the inclusion criteria.

**Surgical Technique:**

All myringoplasty surgeries were executed utilizing the Kerr flap technique by the Author, which included the following steps:

- An elevation of the anterior canal wall and mobilization of the canal skin flap.
- Harvesting a temporalis fascia graft and fashioning it in a rectangular shape with an anterior tab still attached to it.
- Placing the temporalis fascia graft under the perforated tympanic membrane and under the handle of the malleus.
- Carefully pulling the anterior tab of graft from the middle ear through the anteriorly created tunnel.
- Stabilizing the graft with Gel foam both medially and laterally.

**Postoperative Assessment:**

Patients were followed up at 1 month, 3 months and 6 months after the surgery. The Graft uptake rate (the rate at which the graft incorporates in the patient) at the 6-months' follow-up, was the main study endpoint. Other objectives were hearing improvement, tested with air conduction (AC) thresholds and AB gap closure using a pure-tone audiometer. Complications such as infections, residual perforation, or hearing loss were also inquired about.

**Statistical Analysis:**

Data analysis was conducted by the use of the GraphPad program. Descriptive statistics such as median, range and standard deviation were computed. Pre and postoperative hearing thresholds were compared using Wilcoxon matched-pairs signed rank test.

**RESULTS:**

**Patient Demographics:** A total of 118 individuals underwent myringoplasty utilizing the Kerr flap technique, with each case classified according to the age, gender distribution and the operated ear:

**Age Distribution:** The age of the patients ranged from 9 to 60 years, with the largest proportion (36%) falling in the 21–30-year age group, as shown in Figure 1.

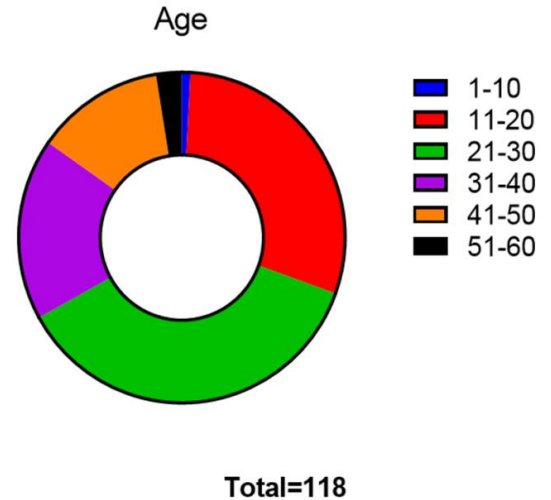


Figure 1: Age distribution of patients

**Gender Distribution:** In the present study, 70.3% of the population were female, as depicted in Figure 2 below.

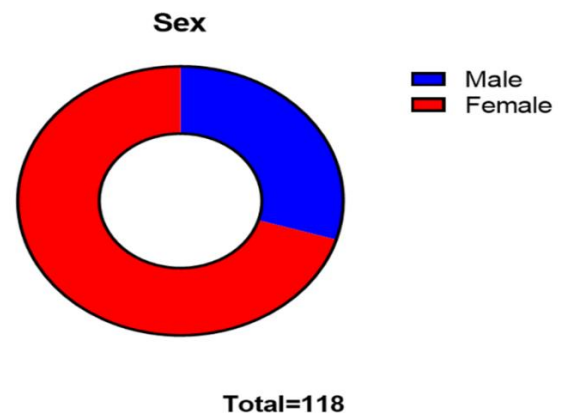
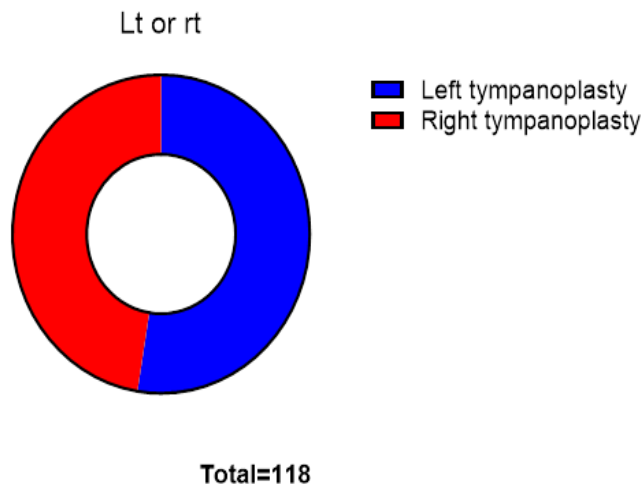


Figure 2: Gender distribution of patients

**Operated Ear:** Distribution showed 52.54% of the total patients underwent Myringoplasty in their Left ear and the remaining in their Right ear as can be seen in Figure 3.



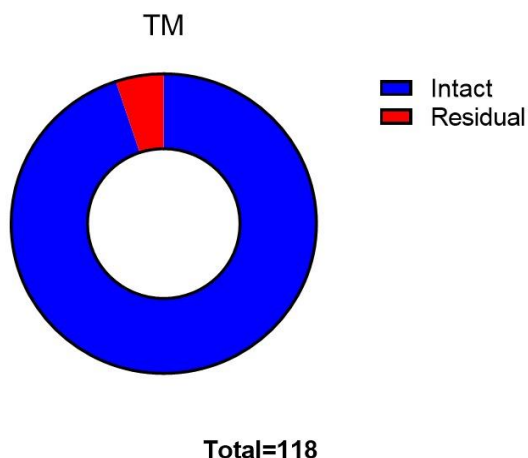
**Figure 3: Distribution of Laterality of Surgery**

No statistically significant difference was found while comparing the groups in age, gender and site of the disease.

**Preoperative and Postoperative Surgical Outcomes:**

Assessment of the hearing status was done using pure tone audiometry and AB gap was calculated before as well as after the surgery. The key findings regarding improvements are as follows:

**Graft Uptake:** At the 6 months' postoperative follow-up, successful graft uptake was seen in 112 patients (94.91%) with Intact TM, whereas 6 patients (5.09%) had a residual perforation.



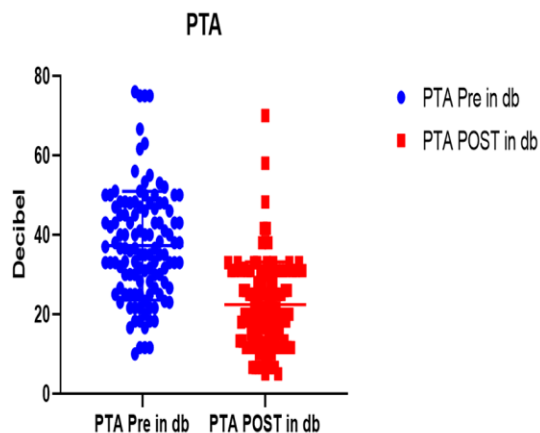
**Figure 4: Graft uptake after surgery.**

**PTA Enhancements and AB gap:** A marked improvement in PTA was observed postoperatively, as indicated in Figure 5 when compared to the preoperative

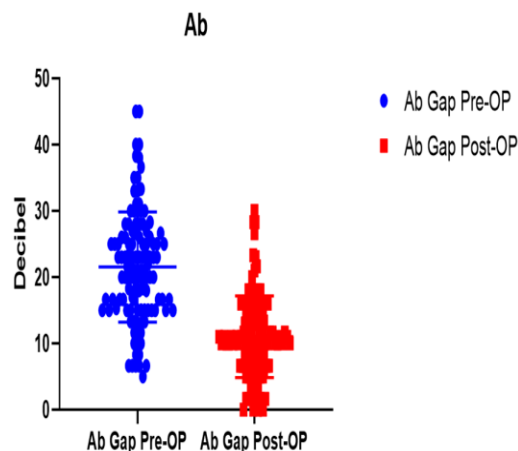
values. A significant difference in both PTA and AB gap values before and after the surgery was observed as shown in the figures ( $p < 0.0001$ ).

A strong relation between PTA values before and after surgery was observed ( $r = 0.76$ ,  $p < 0.05$ ) and a positive relation was also observed between pre and post AB gap ( $r = 0.67$ ,  $p < 0.05$ ).

These strong distributions of data co-relations proved that the patients who already had major initial hearing loss demonstrated greater improvement after undergoing operation with the Kerr flap technique; thus, the Kerr flap method effectively enhanced the auditory restoration depending on the severity of the perforation.



**Figure 5: Distribution of Pre op and Post op PTA values of patients**



**Figure 6: Distribution of Pre op and Post op AB gap values of patients**

**AB Gap closure:** The median closure of the AB gap was at 9.7 dB.

**Surgical Success and Complications:**

It is worth noting that postoperative complications arise very rarely, and in the present study, there was 1 infected case during the analyzed period, which was treated

conservatively. Residual perforation was noted in 5.09% of the population where one patient had performed forceful Valsalva while blowing his nose. There were no occurrences of graft rejection or other significant adverse events documented. The technique is safe and reliable for TM repair based on the high success rate as well as the rarity of complications in TM repair, thus warranting its use, especially when dealing with anterior region perforations. There seems to be no significant lateral predilection of chronic TM perforations in the population. Thus, the present investigation supports the application of the Kerr flap technique in myringoplasty with expectations of excellent outcomes. New drastic improvements in PTA and AB gap values are indicative of the method's effectiveness in repairing related audiological dysfunction as well as the advantage of minimizing complications. These results support the use of the Kerr flap as a useful technique for treating TM perforations of anterior region that offers a stable fixation point and the appropriate anterior segment tension for graft incorporation.

#### **DISCUSSION:**

This study was conducted to evaluate the performance of the Kerr flap in a tertiary care hospital, where we encounter a variety of complex cases that necessitate advanced surgical interventions.

In regions like western Nepal, where healthcare resources may be limited and access to advanced surgical techniques can vary, it is crucial to identify reliable reconstructive options. The Kerr flap, known for its stability and favorable outcomes, was chosen for this study to provide a viable solution for TM reconstruction that can be performed effectively in our setting.

This study confirms the success of the technique used in the case of myringoplasty, as demonstrated by improved auditory gains for TM perforations involving the anterior region. The technique has attracted low rates of complications, which is an added advantage in securing grafts for anterior region perforations. Interestingly, the utility of the Kerr flap, namely, was convenient in creating a stable fixation point and requisite tension to the anterior part of the graft—two potential drawbacks of anterior perforations were thereby resolved, namely, the graft's inability to adhere well enough and poor vascular support.<sup>7,16</sup>

The results of this work show that the Kerr flap technique is effective in anterior region perforation and can provide a significant increase in the indicators of the PTA and effective closing of the AB gap. The ability to secure fixation and sufficient tension in the anterior segment translates into remarkable value in terms of graft stability, especially in anterior perforation scenarios where support is usually wanted.<sup>9,11</sup> Additionally, in posterior perforations where stability is generally not a

significant issue, the use of the Kerr flap method had favorable graft incorporation and auditory rehabilitation outcomes. Regarding the results of this study, the median AB gap closure of 9.7 dB supports earlier data and testifies to the efficiency of the Kerr flap in enhancing conductive hearing, thus making the Kerr flap a dependable tool to rehabilitate hearing consistently after surgery.<sup>8,12</sup>

The present technique of Kerr flap operation in comparison with standard underlay and overlay procedures in myringoplasty offers numerous advantages. Stated anterior perforations imply fewer guarantees of a stable graft, and, more often than not, the underlay does not hold up as much.<sup>13</sup> Despite its suitability for the treatment of large perforations, the overlay technique can cause outcomes like the development of epithelial pearls and retained perforations.<sup>14</sup> On the other hand, there is meticulous placement and tension of the Kerr flap to force the graft to set properly, and the overall graft incorporation is enhanced by a snapshot of the vascular checkup.<sup>15,16</sup> The consistent positioning combined with the applicability of the technique for a wide range of perforations makes the Kerr flap a stable and versatile way to treat the ruptured tympanic membrane.<sup>17,18</sup>

From the literature on the Kerr flap technique, the current low rates of complications are in concordance with those indicated in this study. Six residual perforations were reported, one out of which was due to the patient blowing his nose and performing Valsalva forcefully. One minor infection was reported in the study who was treated conservatively without the requisite for any further surgical interventions. No complications of graft failure or other severe consequences were cited in any of the reported cases. This low complication rate supports the use of the Kerr flap for tympanic membrane repairs, particularly for large anterior perforations where stability of graft attachment is crucial.<sup>16,19</sup>

In the prospective study carried out in a tertiary care center in western part of Nepal, the Kerr flap technique demonstrated effective outcomes in repairing anterior tympanic membrane (TM) perforations, achieving a median AB gap closure of 9.7 dB with only one case of complication managed conservatively. When compared to other similar techniques, Li et al. (2018) employed anterosuperior anchoring with cyanoacrylate glue and the technique did not require the use of gelfoam packing in the middle ear while achieving satisfactory AB gap closure and a low rate of complications, which is in concordance with our findings.<sup>20</sup> On the other hand, Sakalli et al. (2017) have used another graft from the scutum to support anterosuperior perforations, which enhanced stability and reduced postoperative retraction.<sup>21</sup> Although, they reached similar hearing improvement

and low complication incidence, our study of the Kerr flap technique revealed similar stability and comparable functional results without the need for additional adhesives or grafts. These findings present the Kerr flap as a simplified, effective alternative with minimal complications, especially valuable in the tertiary care setting where streamlined yet efficient surgical options are often needed.

Our study reported a notably high graft uptake rate of 94.9% in Kerr flap technique for myringoplasty and it surpassed earlier reported uptake rates. The conventional myringoplasty outcomes typically range between 70-80% for graft uptake, showing the increased efficacy observed in our findings.<sup>22</sup> Moreover, previous research on myringoplasty reported an 83.1% graft uptake rate over one year in 219 patients, with an even higher rate of 88.2% in patients with a normal opposite ear and a lower rate of 75% in patients with tubotympanic Chronic Otitis Media.<sup>23</sup> In comparison, our findings suggest that the Kerr flap technique provides superior graft adherence, which may be particularly beneficial for patients potentially minimizing complications and increasing surgical success rates in diverse patient populations.

We should also note certain limitations of the study. Despite these shortcomings, readers can regard the results of the present study as encouraging. The present study was conducted at a single center, and its subjects were followed up for a relatively short time, which made it impossible to determine how general the results were. Further studies ought to include multi-center and extended observation period studies to understand the specificity of the Kerr flap technique to specific TM perforation types in the long run. Further, in comparisons between the Kerr flap and other surgical techniques as overlay techniques, more light could be shed on the best approaches to managing different types of TM perforations.<sup>12,24</sup>

#### **CONCLUSION:**

It can be stated that the technique of the Kerr flap has a high stability (94.91%) of graft uptake as shown by this study having significant positive shifts in hearing outcomes regardless of the type of perforation. It can be utilized as a stiff and controllable procedure for myringoplasty, which at the same time provides a fixation point and needed tension to the anterior portion of the graft.

**ACKNOWLEDGEMENT:** We are highly grateful to the participants of the study.

**CONFLICT OF INTEREST:** The authors declare no conflict of interest.

#### **REFERENCES:**

1. Wasson JD, Papadimitriou CE, Pau H. Myringoplasty: impact of perforation size on closure and audiological improvement. *J Laryngol Otol.* 2009 Sep;123(9):973-7. doi: 10.1017/S0022215109004368. Epub 2009 Jan 12. PMID: 19134245.
2. Dolhi N, Weimer AD. Tympanic Membrane Perforation. [Updated 2023 Aug 14]. In: StatPearls [Internet]. Treasure Island (FL): StatPearls Publishing; 2024 Jan-. Available from: <https://www.ncbi.nlm.nih.gov/books/NBK557887/>
3. Deptt. Of ENT, Era' Lucknow Medical College & Hospital, India, Kawatra DrR, Maheshwari DrP, Kumar DrG. A Comparative study of the techniques of Myringoplasty - Overlay Underlay & Interlay. *IOSRJDMS.* 2014;13(12):12-6.
4. Le TT, Vo DMN, Duong TM, Nguyen N. Endoscopic transcanal myringoplasty with anterior tab flap underlay technique: An analysis of 35 cases. *Annals of Medicine and Surgery.* 2022 Aug 1; 80:104135.
5. Farrior JB. The anterior tympanomeatal angle in tympanoplasty: surgical techniques for the prevention of blunting. *Laryngoscope.* 1983 Aug;93(8):992-7.
6. Primrose WJ, Kerr AG. The anterior marginal perforation. *Clin Otolaryngol Allied Sci.* 1986 Jun;11(3):175-6. doi: 10.1111/j.1365-2273.1986.tb00125. x. PMID: 3731511.

7. Lakpathi G, Reddy LS, Anand. Comparative Study of Endoscope Assisted Myringoplasty and Microscopic Myringoplasty. *Indian Journal of Otolaryngology and Head & Neck Surgery*. 2016 Mar 21;68(2):185.
8. Caulley L, Hunink MG, Randolph GW, Shin JJ. Evidence-Based Medicine in Otolaryngology, Part XI: Modeling and Analysis to Support Decisions. *Otolaryngol Head Neck Surg*. 2021 Mar 1;164(3):462–72.
9. Faramarzi M, Atashi S, Edalatkah M, Roosta S. The effect of anterior tab flap technique on graft success rate in large tympanic membrane perforation. *Eur Arch Otorhinolaryngol*. 2021 Jun;278(6):1765–72.
10. Singh P, Sinha A, Nagpal R, Chaurasia S. Descemet membrane endothelial keratoplasty: Update on preoperative considerations, surgical techniques, and outcomes. *Indian J Ophthalmol*. 2022 Sep;70(9):3222-3238. doi: 10.4103/ijjo.IJO\_2933\_21. PMID: 36018091; PMCID: PMC9675513.
11. Halik JJ, Smyth GDL. Long-Term Results of Tympanic Membrane Repair. *Otolaryngol--head neck surg*. 1988 Feb;98(2):162–9.
12. Roychaudhuri BK. 3-flap tympanoplasty - A simple and sure success technique. *Indian J Otolaryngol Head Neck Surg*. 2004 Jul;56(3):196–200.
13. Myringoplasty Outcomes From a 5-Year Single Surgeon's Experience and Important Surgical Technical Aspects [Internet]. [cited 2024 Oct 27]. Available from: <https://www.ejao.org/journal/view.php?number=770>
14. Stefan I, Stefanescu CD, Vlad AM, Zainea V, Hainarosie R. Postoperative Outcomes of Endoscopic versus Microscopic Myringoplasty in Patients with Chronic Otitis Media—A Systematic Review. *Medicina*. 2023 Jun;59(6):1074.
15. Myringoplasty - an overview | ScienceDirect Topics [Internet]. [cited 2024 Oct 27]. Available from: <https://www.sciencedirect.com/topics/medicine-and-dentistry/myringoplasty>
16. Murugendrappa MA, Siddappa PN, Shambulingegowda A, Basavaraj GP. Comparative Study of Two Different Myringoplasty Techniques in Mucosal Type of Chronic Otitis Media. *Journal of Clinical and Diagnostic Research: JCDR*. 2016 Feb 1;10(2):MC01.
17. Khoza-Shangase K, Ramdin N. Audiological function in a group of adults following myringoplasty: an exploratory study in South Africa. *The Pan African Medical Journal*. 2019 Sep 27; 34:57.
18. Jain S, Singh SP, Upadhyay VP, Dubey AK, Singh HN. Comparative Study of Advantages and Disadvantages of Endoscopic versus Conventional Myringoplasty—A Prospective Study. *An International Journal of Otorhinolaryngology Clinics*. 2017 Aug 1;10(3):81–6.
19. Wang AY, Liew LJ, Shen Y, Wang JT, von Unge M, Atlas MD, et al. Rat model of chronic tympanic membrane perforation: A longitudinal histological evaluation of underlying mechanisms. *Int J Pediatr Otorhinolaryngol*. 2017 Feb;93:88–96.

20. Li Y, Liang J, Cheng Y, Zhang Q, Ren X, Sheng Y. Anterosuperior anchoring myringoplasty using cyanoacrylate glue can prevent packing gelfoam in the middle ear cavity. *Eur Ann Otorhinolaryngol Head Neck Dis.* 2018 Apr;135(2):95-98. doi: 10.1016/j.anorl.2017.04.002. Epub 2018 Feb 12. PMID: 29449102.
21. E, Celikyurt C, Biskin S, Erdurak SC. A novel myringoplasty technique: the placement of a complementary graft descending from the scutum to support an anterosuperior perforation. *Eur Arch Otorhinolaryngol.* 2017 Jan;274(1):127-131. doi: 10.1007/s00405-016-4254-4. Epub 2016 Aug 11. PMID: 27515708.
22. Vignesh R, Nirmal Coumare V, Gopalakrishnan S, Karthikeyan P. Efficacy of autologous platelet-rich plasma on graft uptake in myringoplasty: a single-blinded randomized control trial. *Egypt J Otolaryngol.* 2022;38(1):6. doi: 10.1186/s43163-021-00190-x. Epub 2022 Jan 15. PMID: PMC8760886.
23. Dangol K, Shrivastav RP. Study of Various Prognostic Factors Affecting Successful Myringoplasty in a Tertiary Care Centre. *Int Arch Otorhinolaryngol.* 2017 Jul;21(3):250-254. doi: 10.1055/s-0036-1593818. Epub 2016 Nov 28. PMID: 28680493; PMID: PMC5495587.
24. Mudry A, Mlynski R, Kramp B. History of otorhinolaryngology in Germany before 1921. *Hno.* 2021 Apr 13;69(5):338.