

Innovative technique of scleral fixated intraocular lens in aphakic patients with inadequate capsular support.

Authors:

Dr. Usha Bhargava, Dr. Shlok O Singh

33/1 Ramprasad Bhargava Marg Ujjain (M.P)

Corresponding Author:

Dr. Shlok O Singh

Assistant professor, 33/1 Ramprasad Bhargava Marg Ujjain (M.P)

Article Received: 12-June-2024, Revised: 02-July-2024, Accepted: 22-July-2024

ABSTRACT:

Methodology: Retrospective study of 43 cases of SFIOL implantation – 28 months, Complete history including details of cataract surgery and trauma. **BCVA & IOP measurement: Slit lamp examination.** * Presence of aphakia * Subluxated lens, traumatic cataract, decentred IOL. * Corneal scarring, vitreous in ac and wound. * Iridodialysis, iris defects, traumatic mydriasis. **Status of anterior & posterior lens capsule:** assessed, CTR with PCIOL implantation in minimally subluxated lens, excluded from our study. **Eyes with intact CCC & inadequate posterior capsule:** secondary PCIOL implantation done & excluded from study. **Gonioscopy:** in blunt trauma cases to rule out angle recession. **Slit lamp biomicroscopy with 78 D:** to rule out CME, macular oedema. Indirect Ophthalmoscopy- posteriorly dislocated lens/IOL, VH, RD, B-Scan, keratometry & biometry.

Results: 43 cases of SFIOL implantation were divided into 4 groups and all groups showed improvement in mean BCVA. **Group 1: SURGICAL APHAKIA s/p complicated cataract Sx (n=16),** Good visual outcome following SFIOL implantation, No significant postoperative (SFIOL) complication. **Divided into 3 subgroups: A) No IOL (n=10) *** BCVA ranged from 6/36 – 6/9. * CME in 2 cases, hence poor vision. **B) Decentred IOL (n=4) *** BCVA ranged from 5/60 – 6/12 * Cause of poor vision: CME (n=1), corneal scar (n=1), NPDR with foveal exudates (n=1) **C) Posteriorly dislocated IOL (n=2) *** SFIOL done along with PPV (n=1) : VA- 6/12, * SFIOL done as second procedure (n=1), VA- 6/24: chronic CME. **Group 2: TRAUMATIC CASES (n=23):** divided into 4 subgroups: **A) Posteriorly dislocated lens (n=4) *** BCVA ranged from CF1ft – 6/12, * SFIOL+PPV in 2 cases, SFIOL as second surgery in 2 cases, * 1 case had associated RD, poor final visual outcome despite, attached retina due to disc pallor. * CME (n=1) * Diffuse macular corneal opacity (n=1) * No complication related to SFIOL. **B) Subluxated Traumatic Cataract (n=5) *** SFIOL + ICCE + Anterior Vitrectomy * BCVA ranged from 6/36-6/12 * IOP was normal before as well as after cataract Sx * Cause of poor vision - chronic CME (n=1); 6/24 - corneal scar s/p repaired corneal tear (n=1); 6/36 * No complication due to SFIOL. **C) Subluxated Traumatic Cataract with Secondary Glaucoma (n=5) *** Trabeculectomy + ICCE + SFIOL * BCVA ranged from 6/24-6/9 * Cause of poor vision :- corneal scar (n=1) *Complication (n=1): Raised IOP, repeat Trab+MMC done 25 days, after initial Sx, IOP subsequently controlled medically, final VA – 6/18. **D) Surgical Aphakia with inadequate capsular support,** s/p Traumatic cataract (TC) Sx (n=9) * SFIOL implanted 1.5 months – 5years after primary Sx (TC Sx in 8, TPPM+PPV in 1 case) * BCVA ranged from CF1ft – 6/9 * SFIOL + PPV (n=2) due to VH – final VA: 6/24, 6/9 * SFIOL+ Optical Iridectomy (n=2) owing to diffuse corneal opacity, s/p corneal tear repair, final VA – CF1ft, 6/24 * This subgroup showed the maximum no. of complications (n=6):

- RD (n=2), noted at 1 & 6 months postoperatively: vitreous exudation was noted in 1 of these 2 cases for which I/V V+C was given, both patients were advised Sx (BB+PPV+SOI) but were lost to f/u.
- Raised IOP (n=3) on first f/u (1week): medically controlled (n=2) along with yag PI (n=1): 1 case required Trab+MMC done 10 days after Sx, IOP being subsequently controlled but had poor final VA due to macular scarring and exotropia.
- Decentration of SFIOL due to broken haptic(n=1) requiring SFIOL exchange

Group 3: Ectopia lentis in Marfan's syndrome (n=3)

* SFIOL + ICCE (n=2), SFIOL + PPL (n=1)

* BCVA ranged from 6/24 – 6/12

* No complication was noted in this group

Group 4) : Optical PK + ACIOL explantation + SFIOL (n=1)

* VH noted postoperatively, resolved spontaneously

* Final VA : 6/36 with clear graft and well centred SFIOL

- All groups showed improvement in mean BCVA in the range
 - * Group 1: 6/36 - 6/9
 - * Group 2: CF1ft – 6/9
 - * Group 3: 6/24 – 6/12
 - * Group 4: 6/36
- Complications included
 - * Mild VH with spontaneous resolution (n=5)
 - * RD (n=2)
 - * Secondary Glaucoma (n=4)
 - * Decentred IOL (n=1)
- Complications were mainly seen in Group 2-D
- Causes of poor vision
 - * Corneal scar (n=6)
 - * CME (n=6)
 - * Macular scar (n=1)
 - * Disc pallor (n=1)
 - * CSMO in NPDR (n=1)
 - * Traumatic mydriasis (n=6)

Conclusion:

- 1) The results indicate that SFIOL implantation is a safe and effective technique for aphakic correction with inadequate capsular support and gives good visual outcome.
- 2) It can be used even in presence of iris defects , diffuse corneal opacity and traumatic mydriasis.
- 3) SFIOL has advantage over ACIOL as it causes little / no corneal endothelial damage and carries reduced risk of secondary glaucoma.
- 4) There are more chances of decentration, uveitis and corneal decompensation with iris fixated IOLs.

Keywords: *scleral fixated intraocular, aphakic patients, inadequate capsular support*

INTRODUCTION:

Aphakia amounts to a visual handicap and use of glasses or contact lens is cumbersome & not practical. Aphakia is annoying complication of cataract surgery. Incidence has dramatically reduced with advent of CCC. Aphakia with inadequate capsular support can occur in a number of cases like,

- 1) Removal of subluxated lens
- 2) Complicated cataract surgery
- 3) Trauma

SFIOL is the best answer to aphakic blindness with good visual outcome, Safe & reasonable technique in eyes with inadequate capsular support Has advantage over ACIOL / iris fixated IOL in presence of large iris defects, diffuse corneal opacity and traumatic mydriasis.

MATERIAL METHODS:

Retrospective study of 43 cases of SFIOL implantation over 28 months
Complete history including details of cataract surgery and trauma

BCVA & IOP measurement

Slit lamp examination

- * Presence of aphakia
- * Subluxated lens, traumatic cataract, decentred

IOL

- * Corneal scarring, vitreous in ac and wound
- * Iridodialysis, iris defects, traumatic mydriasis

Status of anterior & posterior lens capsule: assessed

CTR with PCIOL implantation in minimally subluxated lens, excluded from our study.

Eyes with intact CCC & inadequate posterior capsule: secondary PCIOL implantation done & excluded from study

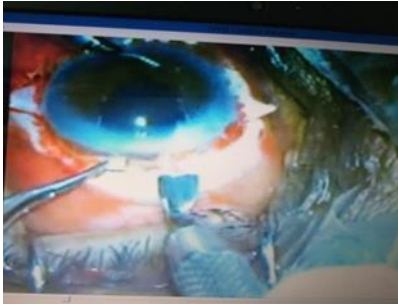Gonioscopy- in blunt trauma cases to rule out angle recession

Slit lamp biomicroscopy with 78 D- to rule out CME, macular oedema

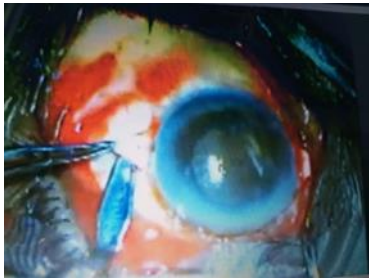Indirect Ophthalmoscopy- posteriorly dislocated lens/IOL, VH, RD, B-Scan, keratometry & biometry.

Surgical Procedure:

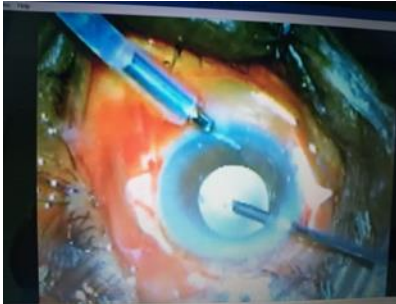
1. Conjunctival peritomy & cauterization.
2. Superior sclerocorneal tunnel for SFIOL implantation.



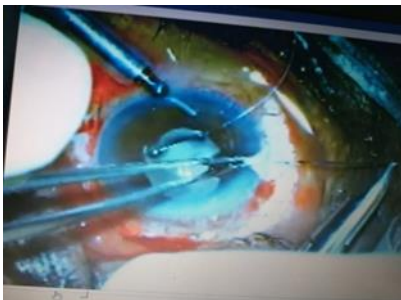3. 2 triangular partial thickness scleral pockets 4 mm from limbus 180° apart at 3 and 9 o'clock positions.



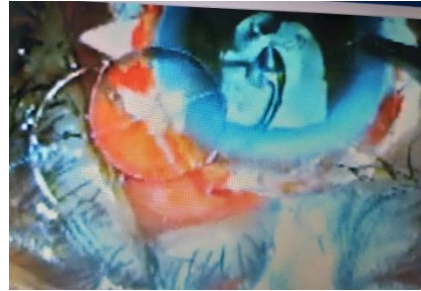4. AC maintainer and anterior automated vitrectomy.



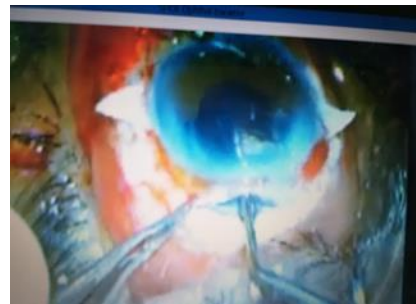
5. 10-0 prolene suture passed from one scleral pocket (1mm from limbus) to the other & pulled with 26 G needle.



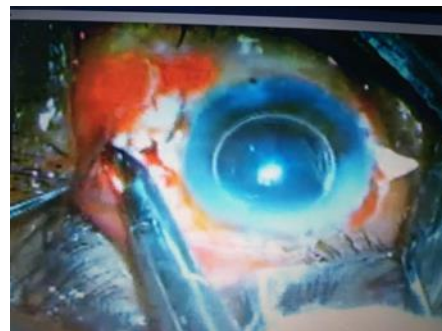6. Suture pulled out through superior tunnel and cut.
7. Cut ends tied with holes of haptics of SFIOL & lens implanted in posterior chamber.



8. Suture on either side pulled snugly to avoid lens tilting.



9. Straight needle of suture bent, passed through bed of scleral pocket and suture tied.
10. Scleral pockets and conjunctiva - sutured with 8-0 vicryl.



11. Subconjunctival injection of antibiotic and steroid.

TABLES:

SR . NO	AGE	SEX	HISTO RY	TIME TO SURG ERY	CLINICA L PRESENT ATION	SURGE RY	SUBSEQUE NT SURGERY	TIME TO SURG ERY(MNT H)	PRE-OP BCVA	POST -OP BCV A	COMPLICATIO NS
1	45	M	TRAU MA – PLANT	2 YRS	APHAKI A,LENS IN VIT CAVITY	ICCE- AV- SFIOL	NIL	-	6/9	6/12	NIL
2	55	M	SICS	1 YR	DISLOCA TED IOL IN ANT VIT CAVITY	IOL EXPAN T-AV- SFIOL	NIL	-	6/24	6/60	MILD VH WITH NPDR WITH FOVEAL EXUDATES
3.	45	M	TRAU MA- WOOD	2 DAYS	POST DISCLOC ATED LENS	PPV- LENSEC TOMY- SF6	SFIOL	6	<6/60	6/12	NIL
4	45	M	TRAU MA- FIST	3 MNTH S	DISLOCA TED LENS IN ANT VIT,VH,T OTAL RD	PPL- PPV-SOI	SOR-SFIOL	6	PR FULL	CF1F T	PALE DISC
5	55	M	TRAU MA CRACK ER	10 DAYS	TC WITH FLAT AC	SICS-AV	PPV-SFIOL	3.5	PR FULL	6/24	NIL
6	22	M	TRAU MA WOOD	1 DAY	CORNEA L TEAR,RU PTURE TC,HYPH AEMA	C.TEAR REPAIR- AC WASH	PPV-SF6- SFIOL	5.5	PR INACC URATE	6/9	RAISED IOL ON 1 ST F/U AFTER SFIOL YAG PI+MED CONTROL,COR NEAL SCAR
7	40	M	CAT+P CIOL	3 YR	LAT DECENT ERD IOL PARTLY IN VIT CAVITY	IOLEXP- AV- SFIOL	NIL	-	6/12	6/12	MILD INFERIOR VH
8	35	M	TRAU MA - HORN	7 YRS	SUBLUX ATED TC	ICCE- AV- SFIOL	NIL	-	6/36	6/24	CHRONIC CME
9	70	M	TRAU MA WOOD	2 YRS	TC WITH ZONULA R DIALYSI S	SICS WITH ANT VIT	SFIOL	3.5	PR FULL	6/18	DRY ARMD
10	22	M	TRAU MA TABLE	1 MNTH	CORNEA L TEAR, RUPTUR	C TEAR REPAIR- AC	PPM-PPV- SFIOL	1.5	PR FULL	6/24	NIL

					TC DEFICIENT IRIS	WASH						
11	30	M	TRAUMA PLANT	1 DAY	GLOBE PERFORATION	C TEAR REPAIR, AC WASH	SFIOL	9	PR INACCURATE	HM		INFERIOR VH F/U 6/18,RD AFETR 6 MNTHS
12	60	M	TRAUMA ROPE	1 MNTH	SUBLUXATED TC, RAISED IOP	TRABICCE - SFIOL	NIL	12	6/18	6/9		LITTLE CORTEX IN VITREOUS ABSORBED OVERTIME
13	60	M	SICS	1 YR	APHAKIA,PCR	AV-SFIOL	NIL	-	HM	6/12		NIL
14	65	M	SICS	7 MNTHS	APHAKIA,PCR	AV-SFIOL	NIL	-	HM	6/9		NIL
15	80	M	SICS	3 MNTHS	APHAKIA	AV-SFIOL	NIL	-	6/18	6/12		MILD INFERIOR VH
16	40	M	TRAUMA	2 MNTHS	LENS IN AC,CORNEAL EDEMA RAISED IOP	TRABICCE-AV-SFIOL	NIL	-	1/60	6/18		INFERIOR VH WITH MACULAR EDEMA
17	63	M	SICS	6 MNTHS	APHAKIA,CHRONIC CME,POST DISLOCATED IOL	PPV-IOL EXPLANATION	SFIOL	8	6/36	6/24		CHRONIC CME
18	26	F	SICS	3 MNTHS	APHAKIA PCR	AV-SFIOL	NIL	-	6/9	6/12		NIL
19	6	F	TRAUMA STONE	15 DAYS	RUPTURED TC, UVEITIS	SICS-PCIOL	IOL EXPLANT-SFIOL	1.5	PR	6/36		CORNEAL SCAR.P.O UVEITIS
20	65	M	TRAUMA WOOD	1 DAY	REPAIRED CORNEAL TEAR,SUBLUXATED TC, TM	ICCE-AV-SFIOL	NIL	-	PR FULL	6/36		CORNEAL SCAR
21	8	M	TRAUMA CRAKER	1 HR	CORNEAL ABRASION,HYPHAEMA	ICCE,AC WASH	AV-SFIOL	1.5	1/60	CF2FT		RD AND VIT EXUDATES
22	18	M	POOR VN	-	ECTOPIA LENTIS	PPL-SFIOL	NIL	-	6/36	6/24		NIL
23	25	M	POOR	-	ECTOPIA	ICCE-	NIL	-	3/60	6/12		NIL

			VN		LENIS	SFIOL						
24	35	M	POOR VN	-	ECTOPIA LENTIS	ICCE- SFIOL	NIL	-	3/60	6/24	NIL	
25	59	M	SICS	6 MNTH S	APHAKI A,NO CAPSUL E	AV- SFIOL	NIL	-	6/18	6/9	NIL	
26	60	M	TRAU MA STONE	3 DAYS	SUBLUX ATED TC,TM,HI GH IOP SHALOW AC	TRAB- ICCE- SFIOL	TRAB-MMC	1	1/60	6/18	HIGH IOP	
27	35	F	ICCE	1.5 MNTH S	APHAKI A,VIT IN AC	AV- SFIOL	NIL	1	6/18	6/18	NIL	
28	5	F	TRAU MA ARRO W	1 DAY	APHAKI A,REPAI RED CORNEA L TEAR,AD HERENT LEUCOM A	AV- SFIOL	NIL	2	CFCF	CF1F T	DIFFUSE CO,HIGH IOL,CONTROL LED MEDICALLY	
29	20	F	SICS s/p TRAU MA	5 YRS	APHAKI A,EXOTR OPIA	SFIOL- PI	TRAB- SFIOL EXCHANGE	1	6/36	6/36	HIGH IOP,TRAB DONE,DECENT ERED IOL,BROKEN HAPTIC	
30	69	M	SICS	1 YR	BAD APHAKI A,SCLER AL THINNIN G,IRIS DEFICIE NT	AV- SFIOL- CORNE AL SECTIO N	NIL	1	5/60	6/36	CHRONIC CME	
31	70	M	TRAU MA STONE	21 DAYS	MARKED SUBLUX ATED CATARA CT,LARG E ID,TM	TRB- ICCE- SFIOL	NIL	2.5	5/60	6/18	NIL	
32	50	M	TRAU MA WOOD	1 YR	SUBLUX ATED TC	ICCE- SFIOL	NIL	1.3	6/36	6/18	NIL	
33	70	F	?TRAU MA	1 YR	SUBLUX ATED CATARA CT	ICCE- SFIOL	NIL	1.5	CFCF	6/24	MILD INFERIOR VH	
34	70	M	TRAU MA PLANT	1 YR	SUBLUX ATED CATARA	ICCE- DROPPE D	NIL	1	6/36	6/24	CME	

					CT,TM,M YOPIC RET DEGEN	CATAR ACT- PPV- SFIOL						
35	50	M	TRAU MA THORN	5 MNTH S	APHAKI A,REPAI RED CORNEA L TEAR	SFIOL- OPTICA L IRIDEC TOMY	NIL	2	6/36	6/24	DIFFUSE CORNEAL SCAR	
36	40	M	TRAU MA WOOD	6 DAYS	SUBLUX ATED TC,AC SHALLO W,HYPH AEMA	TRAB- ECCRE- AV- SFIOL	NIL	3	1/60	6/24	CORNEAL SCAR,MACULA R EDEMA	
37	70	M	SICS	7 MNTH S	BAD APHAKI A,CME	AV- SFIOL	NIL	0.3	6/60	6/36	EMM,S/P CME	
38	67	M	CAT SX	7 MNTH S	APHAKI A,VIT IN A,IRIS DEFICIE NT	AV- SFIOL- PI	NIL	2	6/9	6/12	NIL	
39	55	F	CAT IOL	6 MNTH S	DECENT ERED IOL,CME	IOL EXPLA NT- SFIOL	NIL	3	CF1FT	6/18	CME	
40	62	F	TRAU MA	8 MNTH S	CATARA CT WITH GLAUCO MA	TRAB- SICS- PCR- SFIOL	NIL	9	5/60	6/9	NIL	
41	50	F	TRAU MA STONE	7 MNTH S	REPAIRE D CORNEA L TEAR,PO ST DISLOCA TED LENS	PPV- LENSEC TOMY- SFIOL	NIL	3	HM	6/36	HIGH IOP,DIFFUSE MACULAR OPACITY	
42	63	M	CAT- IOL	10 DAYS	POST DISLOCA TED IOL,LEN S MATTER IN AC	PPV-IOL EXPLA NT- SFIOL	NIL	7	1/60	6/12	NIL	
43	60	F	CAT- IOL	1 YR	DECOMP ENSATE D CORNEA	PK- ACIOL EXPLA NT- SFIOL	NIL	6	HM	6/36	INFERIOR VH	

RESULTS:

43 cases of SFIOL implantation were divided into 4 groups and all groups showed improvement in mean BCVA

Group 1: SURGICAL APHAKIA s/p complicated cataract Sx (n=16)

Good visual outcome following SFIOL implantation

No significant postoperative (SFIOL) complication

Divided into 3 subgroups:

Group 1:

A) No IOL (n=10)

* BCVA ranged from 6/36 – 6/9

* CME in 2 cases, hence poor vision

B) Decentred IOL (n=4)

* BCVA ranged from 5/60 – 6/12

* Cause of poor vision :

CME (n=1), corneal scar (n=1), NPDR with foveal exudates (n=1)

C) Posteriorly dislocated IOL (n=2)

* SFIOL done along with PPV (n=1) : VA- 6/12

* SFIOL done as second procedure (n=1), VA-6/24: chronic CME

Group 2: TRAUMATIC CASES (n=23) – divided into 4 subgroups:

A) Posteriorly dislocated lens (n=4)

* BCVA ranged from CF1ft – 6/12

* SFIOL+PPV in 2 cases, SFIOL as second surgery in 2 cases

* 1 case had associated RD, poor final visual outcome despite

attached retina due to disc pallor

* CME (n=1)

* Diffuse macular corneal opacity (n=1)

* No complication related to SFIOL

B) Subluxated Traumatic Cataract (n=5)

* SFIOL + ICCE + Anterior Vitrectomy

* BCVA ranged from 6/36-6/12

* IOP was normal before as well as after cataract Sx

* Cause of poor vision

- chronic CME (n=1); 6/24

- corneal scar s/p repaired corneal tear (n=1); 6/36

* No complication due to SFIOL

C) Subluxated Traumatic Cataract with Secondary Glaucoma (n=5)

* Trabeculectomy + ICCE + SFIOL

* BCVA ranged from 6/24-6/9

* Cause of poor vision :- corneal scar (n=1)

* Complication (n=1): Raised IOP, repeat Trab+MMC done 25 days

after initial Sx, IOP subsequently controlled medically, final VA – 6/18

D) Surgical Aphakia with inadequate capsular support, s/p Traumatic cataract (TC) Sx (n=9)

* SFIOL implanted 1.5 months – 5years after primary Sx (TC Sx in 8,

TPPM+PPV in 1 case)

* BCVA ranged from CF1ft – 6/9

* SFIOL + PPV (n=2) due to VH – final VA: 6/24, 6/9

* SFIOL+ Optical Iridectomy (n=2) owing to diffuse corneal opacity, s/p

corneal tear repair, final VA – CF1ft, 6/24

* This subgroup showed the maximum no. of complications (n=6):

- RD (n=2), noted at 1 & 6 months postoperatively: vitreous exudation

was noted in 1 of these 2 cases for which I/V V+C was given, both

patients were advised Sx (BB+PPV+SOI) but were lost to f/u.

- Raised IOP (n=3) on first f/u (1week): medically controlled (n=2) along

with yag PI (n=1): 1 case required Trab+MMC done 10 days after Sx,

IOP being subsequently controlled but had poor final VA due to macular

scarring and exotropia.

- Decentration of SFIOL due to broken haptic(n=1) requiring SFIOL

exchange

Group 3): Ectopia lentis in Marfan's syndrome (n=3):

* SFIOL + ICCE (n=2), SFIOL + PPL (n=1)

* BCVA ranged from 6/24 – 6/12

* No complication was noted in this group

Group 4): Optical PK + ACIOL explantation + SFIOL (n=1):

* VH noted postoperatively, resolved spontaneously

* Final VA : 6/36 with clear graft and well centred SFIOL

• All groups showed improvement in mean BCVA in the range

* Group 1: 6/36 - 6/9

* Group 2: CF1ft – 6/9

* Group 3: 6/24 – 6/12

* Group 4: 6/36

• Complications included

* Mild VH with spontaneous resolution (n=5)

* RD (n=2)

* Secondary Glaucoma (n=4)

* Decentred IOL (n=1)

- Complications were mainly seen in Group 2-D
- Causes of poor vision
 - * Corneal scar (n=6)
 - * CME (n=6)
 - * Macular scar (n=1)
 - * Disc pallor (n=1)
 - * CSMO in NPDR (n=1)
 - * Traumatic mydriasis (n=6)

DISCUSSION:

Scleral fixation of IOL is a boon to aphakic patients with inadequate capsular support. Transscleral IOL suturing was introduced in the 1980s. Dr. Wafapoor performed 30 foldable IOLs between Aug'2001 and April'2003 at University of Mississippi & reported his study^[1] -

* All his patients achieved final VA of 6/12 or better, except one with CME.

* Complications included glaucoma (n=3), VH requiring PPV (n=1), pupillary capture of IOL (n=1), suture wick endophthalmitis (n=1) and CME (n=1).

Dr. Rupam desai et al compared the study of scleral fixation with ACIOL and reported comparable visual outcome with good PO comfort with SFIOL than ACIOL^{[2][3]}.

Our efficacy and safety outcomes compare favourably with those reported in numerous studies^[4-9], 50% of eyes in our series were post-trauma and thus at increased risk to develop glaucoma and retinal complications.

Scleral suturing of SFIOL is not an innocuous procedure^[10]. Leaving a non-absorbable suture permanently in place raises the possibility for suture wick endophthalmitis, no such incidence found in our study^[11]. Pigment deposits on IOL may be considered a visually significant complication with potential for secondary glaucoma. This is more likely to be seen with foldable SFIOL placed in sulcus than rigid SFIOL. Iris fixated and ACIOLs have been described to cause more pigment dispersion. Placement of flaps at 3 and 9 o'clock carries the potential for bleeding from posterior ciliary arteries. Single arm suture fixation is more commonly associated with knot externalization and the potential for long term exposure with endophthalmitis & IOL tilt. Use of 10-0 polypropylene suture material can lead to late suture hydrolysis in a subset of patients. There is hence need to explore other suture materials which do not biodegrade, viz polytetrafluoroethylene (GoreTex) and techniques.

CONCLUSION:

1) The results indicate that SFIOL implantation is a safe and effective technique for aphakic correction with inadequate capsular support and gives good visual outcome.

2) It can be used even in presence of iris defects, diffuse corneal opacity and traumatic mydriasis.

3) SFIOL has advantage over ACIOL as it causes little / no corneal endothelial damage and carries reduced risk of secondary glaucoma.

4) There are more chances of decentration, uveitis and corneal decompensation with iris fixated IOLs.

CONFLICTS OF INTEREST: None

REFERENCES:

1. Guttman, Cheryl. "Sutured IOL an alternative when capsular support is lacking: posterior chamber lens placement through clear corneal incision can provide treatment option." *Ophthalmology Times*, vol. 29, no. 17, 1 Sept. 2004, p.
2. Yalniz-Akkaya Z, Burcu A, Uney GO, Abay I, Eksioğlu U, Acar MA, Ornek F. Primary and secondary implantation of scleral-fixated posterior chamber intraocular lenses in adult patients. *Middle East Afr J Ophthalmol*. 2014 Jan-Mar;21(1):44-9. doi: 10.4103/0974-9233.124093.
3. Singh, Shambu and Divyalakshmi / *IP International Journal of Ocular Oncology and Oculoplasty* 2023;9(4):182-185
4. Cheng KKW, Tint NL, Sharp J, Alexander P. Surgical management of aphakia. *J Cataract Refract Surg*. 2022;48(12):1453-61.
5. Kelkar AS, Kelkar J, Bhende P, Narayanan R, Maiti A, Bolisetty M, et al. Preferred practice patterns in aphakia management in adults in India: A survey. *Indian J Ophthalmol*. 2022;70(8):2855-60.
6. Apple D, Mamalis N, Loftfield K. Complications of intraocular lenses: a historical and histopathological review. *Surv Ophthalmol*. 1984;29(1):54. doi:10.1016/0039-6257(84)90113-.
7. Stark WJ, Gottsch JD, Goodman DF, Goodman GL, Pratzler K. Posterior chamber intraocular lens implantation .in the absence of capsular support. *Arch Ophthalmol*. 1989;107(7):1078-83.
8. Holladay JT. Evaluating the intraocular lens optic. *Surv Ophthalmol*. 1986;30(6):385-90.
9. Available from: <https://www.sciencedirect.com/science/article/am/pii/S0181551220300474>.

10. Kokame GT, Yanagihara RT, Shantha JG, Kaneko KN. Longterm outcome of pars plana vitrectomy and sutured scleral-fixated posterior chamber intraocular lens implantation or repositioning. *Am J Ophthalmol.* 2018;189:10–6. doi:10.1016/j.ajo.2018.01.034.
11. Chia-Yi Cheng, Yu-Bai Chou, Chia-Ying Tsai, Ming-Hung Hsieh, Chia-Chieh Hsiao, Tso-Ting Lai, Management of complications of sutureless intrascleral intraocular lens fixation, *Taiwan Journal of Ophthalmology*, 10.4103/tjo.TJO-D-23-00163, 14, 1, (95-101), (2024).