

## Enhanced Recovery in Bariatric Surgery through Opioid-Free Anesthesia: A Clinical Case Report

### Authors:

Dr. Said Omar Jaro, Dr. Hany Fawzi W. Greiss, Dr. Osama Sami Maki Al Ani, Dr. Osama Ahmed Mohamed Elhanfi

RASHID HOSPITAL, DUBAI ACADEMIC HEALTH CORPORATION . DUBAI, UAE .

### Corresponding Author:

Dr. Said Omar Jaro

Article Received: 27-April-2024, Revised: 17-May-2024, Accepted: 07-June-2024

### **ABSTRACT:**

Opioid-free anesthesia management was a new aspect explored in this case study report concerning a 32-year-old male who underwent laparoscopic sleeve gastrectomy. Pre-anesthesia evaluation was a general medical examination seeking to capture his medical information and his physical condition. Concurrently, in the operating room (OR) opioid-free anesthesia was secured with dexmedetomidine, lidocaine, magnesium sulfate, propofol and ketamine; which was propelled by sevoflurane maintenance. Subsequently, post-operatively, titrated infusion of dexmedetomidine and ketamine with respect to patient-controlled analgesia proved to be more effective in controlling pain than opioids and the patient was hemodynamically well-stabilized and also better avoided side-effects associated with opioids. This case evidenced that it is possible and beneficial to create care pathways without opioids to substitute for pain and opioid medication control. It is also a successful part of the Enhanced Recovery After Surgery (ERAS) framework.

**Keywords:** *Bariatric surgery, dexmedetomidine, enhanced recovery after surgery, ketamine, opioid-sparing analgesia*

### **INTRODUCTION:**

Bariatric surgery, a salvageable treatment for very obese person, is a potentiality to have long-term results like weight loss that is sustainable, metabolic comorbidities resolution, and even increased lifespan [1]. With the fast-growing demand for bariatric surgeries around the globe, the best option is to optimize all perioperative care systems in place. A new exciting approach is Enhanced Recovery After Surgery (ERAS), which is a concept that is based on reliable studies and designed to lead to better results [2].

The ERAS Society has generated treatment protocols that are based on the scientific data and are for the perioperative care of patients undergoing bariatric surgery. The recommendations are divided into a few sections which include pre-operative procedures, anesthetic management intraoperatively and outpatient surgery recovery [3]. Following up executive treatment protocols of healthcare providers can help patients gain advantages and even avoid complications.

Opioids can be described as mainstays of analgesia in anesthesia, not only in the operating theater but also in cases of pain management postoperatively. It is a fact that the use of opioids is associated with several adverse

effects which include respiratory depression, addiction, and prolonged recovery, as the result thereof a reevaluation of this approach became inevitable [4]. The opioid-free anesthesia, which entails the replacement of opioids with alternatives that present lower or no risk of opioid use, is a great approach. The research indicated that an advanced recovery plan greatly reduces the opioid demand during the perioperative process and postoperative vomiting in the bariatric surgery patients [5].

Managing pain well continues to be a challenge in bariatric surgery; however, because of the specific characteristics of people who are very overweight, this is particularly the case. Getting best out of pain-relieving agents while preventing the opioid related complications involve the composite approach. Alternative approaches besides opioids, such as regional anesthesia tactics, NSAIDs, and acetaminophen, are very influential when it comes to pain management and simultaneously reducing undesirable effects [6].

The evidence for the ERAS interventions in gastric bypass exchanges from rather lowly ratings that need to be generalized across different surgical contexts. Nevertheless, nowadays up-to-date documents highlight

that in order to eliminate narcotic anesthesia and pain treatment need multimodal therapy. Through the presence of regionally block NSAIDs and motilities, including nonopioid modalities, clinicians can lead to fast recovery of the patient and decrease the length-of-stay only by the numbers [7].

**Case Presentation:**

**Patient Information:** A 32-year-old male with a body mass index (BMI) of 35 presented for a laparoscopic sleeve gastrectomy. His medical history is known to have antisocial personality disorder, following with psychiatry, positive history of Substance abuse, and obesity.

**Pre-Anesthesia Evaluation:** Routine pre-anesthesia evaluation was conducted a day before the surgery. This included a thorough medical history, physical examination, and investigations such as ECG, chest X-ray (CXR), pulmonary function tests (PFT), and laboratory tests (complete blood count (CBC) and electrolytes). Both procedure and anesthesia consents were obtained.

**Intraoperative Management:** Upon arrival in the operating room, the patient was positioned in the ramp position to improve the laryngoscopic view of the glottis opening and facilitate airway management. Pre-

oxygenation was achieved using continuous positive airway pressure (CPAP) with 100% FiO<sub>2</sub>.

**Pre-medication and Induction:** Dexmedetomidine was administered as a bolus dose of 1 mcg per predicted body weight over 10 minutes, followed by a maintenance dose of 0.5 mcg/kg/hr. Lidocaine 100 mg IV bolus was given once, and magnesium sulfate 2 grams in 50 ml normal saline was infused over 10 minutes. Propofol 200 mg IV and ketamine 30 mg IV were administered. Suxamethonium 1.5 mg per actual body weight was used for muscle relaxation, followed by rocuronium 50 mg after securing the airway. Intubation was performed using the rapid sequence induction (RSI) technique.

**Maintenance of Anesthesia:** Antibiotics were administered intravenously. Anesthesia was maintained with sevoflurane at 2%. Antiemetics, analgesics (Perfalgan, Dynastat), and a proton pump inhibitor (pantoprazole) were given. Fentanyl was reserved as a rescue medication for persistent hypertension (BP > 150/90) or tachycardia (HR > 120 bpm), but it was not required as the patient remained hemodynamically stable. Throughout the course of anesthesia, the patient’s vital signs (heart rate, blood pressure, SpO<sub>2</sub>) remained within normal limits (Figure 1).

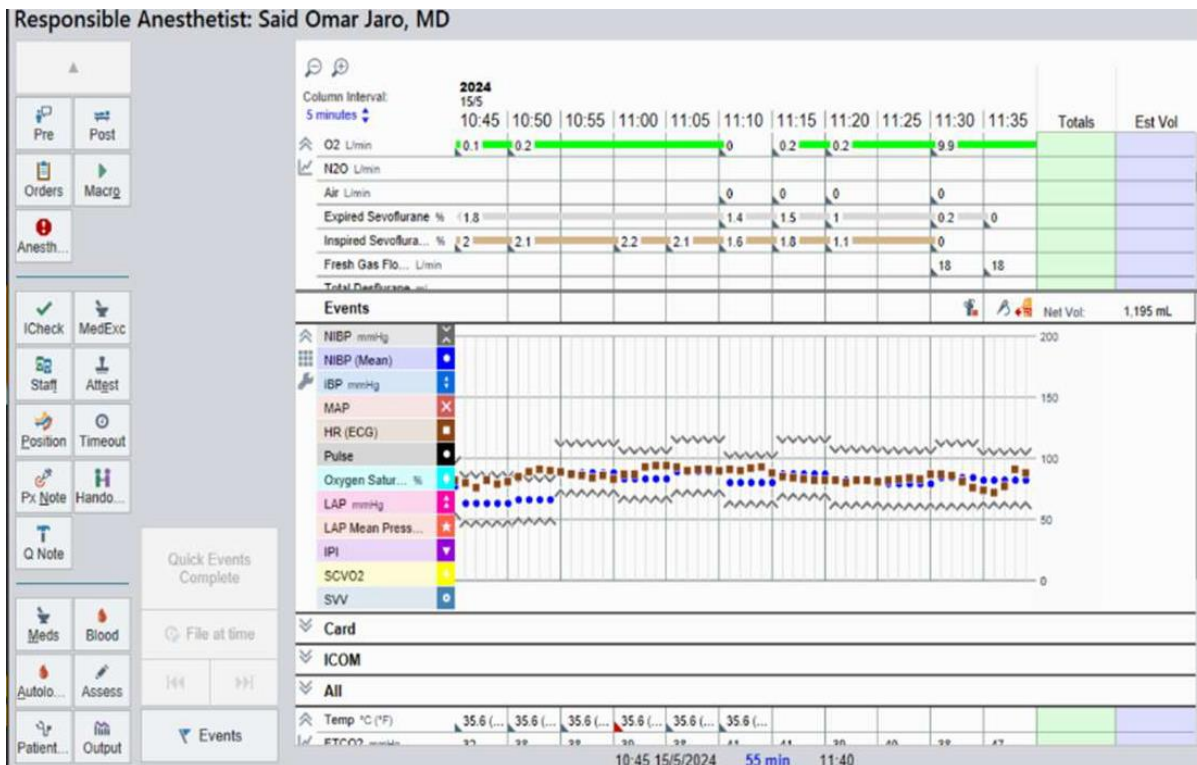


Figure 1 Intraoperative management, all vital signs are stable

**Post-Anesthesia Care Unit (PACU):** In the PACU, patient-controlled analgesia (PCA) was initiated with a mixture of dexmedetomidine 100 mcg and ketamine 50 mg in 48 ml normal saline (2 mcg + 1 mg/ml), with a bolus dose of 1 ml and a lockout time of 5 minutes. No morphine was added. Upon extubation, the patient reported no pain, nausea, or vomiting. Vital signs remained stable. Later on in the PACU, patient complained a moderate pain, with pain score 4/10, requiring two clinician boluses of the PCA with 3 ml each, paracetamol 1 gram iv given as well, pain subsided and the patient was discharged from PACU to the ward after 60 minutes.

**Ward Care:** In the ward, the patient continued to receive Perfalgan 1g IV every six hours, Dynastat 40 mg IV twice daily, pantoprazole 40 mg IV once daily, and ondansetron as needed. PCA with dexmedetomidine and ketamine was maintained as previously described, PCA consumption has calculated, it showed that he consumed 34 ml from the PCA over 24 hours with pain score between 2-4 over 24 hours post operatively. Patient has been discharged home in day one post operatively as recommended by general surgeon with stable condition and controlled pain.

**Outcomes:** The patient remained hemodynamically stable throughout the perioperative period, with heart rate, blood pressure, and SpO<sub>2</sub> within normal limits. The use of opioid-free anesthesia successfully avoided the common side effects associated with opioids, such as nausea, vomiting, constipation, urinary retention, bowel ileus, and the risk of addiction.

## **DISCUSSION:**

In this case report, the streamlined administration of opioid-free anesthesia (OFA) in a 32-year-old man scheduled for laparoscopic sleeve gastrectomy is illustrated. Basing the implementation of OFA on the much widely known side effects that opioids cause including nausea, vomiting, constipation, urinary retention and addiction was the major decision driving the implementation process [8]. The success of opioid-free anesthesia OFA in the perioperative care of bariatric surgery is demonstrated here because it was able to produce similar analgesic effects without the adverse reactions that had been associated with opioids.

The intravenous Dexmedetomidine being part of the premedication protocol was a potent tool in maintaining the intraoperative hemodynamic stability. Its sedative properties coupled with anaesthetic and sympatholytic effects have been repeatedly confirmed. As in the work done by Kaye et al., they show that dexmedetomidine effectively furnishes sedation minus causing substantial

respiratory depression as observed in our procedure where the vital signs steady throughout [9]. Besides, Shin et al. discovered that the use of dexmedetomidine is high in the occurrence of postoperative delirium, yet another evidence of successful use of this preparation in improvement of patient's outcome [10].

The attempt of using lidocaine and magnesium sulfate before intubation to soften up the stress response was motivated by the ease that Chu et. Al., had demonstrated using intravenous lidocaine infusions as an effective management for pain caused by both postoperative and neuropathic stress conditions [11].

In intraoperatively propofol and ketamine along with their cofactor were responsible for balanced anesthesia and analgesia. Ketamine, which is the best example is of an NMDA receptor antagonist, is also very effective in the reduction of postoperative pain and the intake of opioids as it is showed in the study of Bell et al. from the complex spine surgeries [13]. The combination of ketamine with propofol made possible for better pain control and sedation which reestablished patient's stability [14].

In the postoperative period following PCA (Intravenous patient-controlled analgesia) with dexmedetomidine and ketamine, it was clearly seen that was beneficial. Like a trial carried out by Elvir-Lazo et al., as an example non-opioid substances can help to significantly improve satisfaction of the patient and decline the rates of PONV through the PCA method [15]. Such observation corresponds to the indications of patient's adequate orientation with the expiration of oxygen-restricted breathing.

Fanatical nursing care with pain killers like Perfalgan (paracetamol) and Dynastat (parecoxib) was able to provide pain relief that did not have side effects that are associated with opioid. A proven pain reliever between paracetamol and parecoxib has been indicated in multiple research papers, such as Anderson explaining paracetamol's analgetic mechanism [16], and Essex et al., showing parecoxib's capability in decreasing pain [17].

The outcome demonstrates the increasing evidence base of OFA, a contended intervention that facilitates bariatric surgery leading to a hemodynamically stable and opioid-related complications free procedure. This study shows that the use of OFA protocol can help in patients' full recovery, speed up their discharge from the hospital and the risk of long-term opioid addiction may be reduced. The patient's smooth recovery and early discharge present these advantages, thus implying that OFA may well become an efficient substitute of the traditional opioid-based anesthesia in patients undergoing bariatric surgery.

## **Clinical Implications and Future Recommendations:**

This case serves as a reflection of the dramatic effect opioid-free anesthesia (OFA) has on the bariatric patients, especially with respect to pain management and postoperative status. An achievement that should be noted is the drug-free and side effects-less protocols, e. g. nausea, vomiting, constipation and addiction potentially, in particular. The case is example of how an OFA protocol with the OFA agents like dexmedetomidine, ketamine and lidocaine, and magnesium sulfate can be used effectively to bring about analgesia and hemodynamic stability, thus, improving outcomes for the patients and patient satisfaction.

The recommendations as future studies are that hold large to larger, randomized controlled trials to confirm the efficacy of OFA towards various surgical groups, for instance and including bariatric procedures. It is also important to identify the longer-term effects post OFA, that is, the prevalence of chronic pain, patient's quality of life improved and slowing down the patient regarding the long-term opioid dependence. Providing trainings and educational programs for anesthesiologists and surgical teams should likewise enfavor OFA principles and techniques, assuring the comparable adoption of the modality across different clinical atmospheres. The growth in evidence-based relevance of OFA, in the near future it is expected that it would become a foundation of modern perioperative medicine, by aligning with the goals of ERAS for the success of patients and overall healthcare outcomes.

## **CONCLUSION:**

The application of OFA in the laparoscopic sleeve gastrectomy of the 32-year male patients with diabetes mellitus, hypertension, and obesity has been extremely efficient. A combination of multimodal anesthesia regimes is applied which was composed of dexmedetomidine, ketamine, lidocaine, and magnesium sulphate. Even though it provides effective post-operative pain, it also keeps hemodynamic conditions in stable range. Another significant attraction is that this method made opioids unnecessary, and this in turn reduced the well-known nausea, vomiting, constipation, and risk of addiction, which result from that medication. These results ensure the accuracy and safety of OFA in the bariatric surgery operation and shows its broader application can definitely lead better outcomes and better satisfaction with patients. Also, more studies and medical staff willing to apply OFA protocols in their daily clinical practice will open up more possibilities for such patients to have better recovery after surgery.

## **REFERENCES:**

1. Ragavan S, Elhelw O, Majeed W, Alkhaffaf B, Senapati S, Ammori BJ, et al. Weight Loss Following Bariatric Surgery in People with or without Metabolic Syndrome: A 5-Year Observational Comparative Study. *Journal of Clinical Medicine*. 2024;13(1):256.
2. Forster C, Gonzalez M. Enhanced recovery after surgery (ERAS): philosophy, theory and practice. *J Thorac Dis*. 2022;14(10):3684-7.
3. Stenberg E, Dos Reis Falcão LF, O'Kane M, Liem R, Pournaras DJ, Salminen P, et al. Guidelines for Perioperative Care in Bariatric Surgery: Enhanced Recovery After Surgery (ERAS) Society Recommendations: A 2021 Update. *World J Surg*. 2022;46(4):729-51.
4. Algera MH, Kamp J, van der Schrier R, van Velzen M, Niesters M, Aarts L, et al. Opioid-induced respiratory depression in humans: a review of pharmacokinetic&#x2013;pharmacodynamic modelling of reversal. *British Journal of Anaesthesia*. 2019;122(6):e168-e79.
5. King AB, Spann MD, Jablonski P, Wanderer JP, Sandberg WS, McEvoy MD. An enhanced recovery program for bariatric surgical patients significantly reduces perioperative opioid consumption and postoperative nausea. *Surg Obes Relat Dis*. 2018;14(6):849-56.
6. Abdolrazaghnejad A, Banaie M, Tavakoli N, Safdari M, Rajabpour-Sanati A. Pain Management in the Emergency Department: a Review Article on Options and Methods. *Adv J Emerg Med*. 2018;2(4):e45.
7. Ghai B, Jafra A, Bhatia N, Chanana N, Bansal D, Mehta V. Opioid sparing strategies for perioperative pain management other than regional anaesthesia: A narrative review. *J Anaesthesiol Clin Pharmacol*. 2022;38(1):3-10.
8. Bohringer C, Astorga C, Liu H. The Benefits of Opioid Free Anesthesia and the Precautions Necessary When Employing It. *Transl Perioper Pain Med*. 2020;7(1):152-7.
9. Kaye AD, Chernobylsky DJ, Thakur P, Siddaiah H, Kaye RJ, Eng LK, et al. Dexmedetomidine in Enhanced Recovery After Surgery (ERAS) Protocols for Postoperative Pain. *Curr Pain Headache Rep*. 2020;24(5):21.
10. Shin H-J, Woo Nam S, Kim H, Yim S, Han S-H, Hwang J-W, et al. Postoperative Delirium after Dexmedetomidine versus Propofol Sedation in Healthy Older Adults Undergoing Orthopedic

Lower Limb Surgery with Spinal Anesthesia: A Randomized Controlled Trial. *Anesthesiology*. 2023;138(2):164-71.

11. Chu R, Umukoro N, Greer T, Roberts J, Adekoya P, Odonkor CA, et al. Intravenous Lidocaine Infusion for the Management of Early Postoperative Pain: A Comprehensive Review of Controlled Trials. *Psychopharmacol Bull*. 2020;50(4 Suppl 1):216-59.

12. Ozen M, Xie H, Shin N, Al Yousif G, Clemens J, McLane MW, et al. Magnesium sulfate inhibits inflammation through P2X7 receptors in human umbilical vein endothelial cells. *Pediatr Res*. 2020;87(3):463-71.

13. Bell RF, Kalso EA. Ketamine for pain management. *Pain Rep*. 2018;3(5):e674.

14. Arora S. Combining ketamine and propofol ("ketofol") for emergency department procedural sedation and analgesia: a review. *West J Emerg Med*. 2008;9(1):20-3.

15. Elvir-Lazo OL, White PF, Yumul R, Cruz Eng H. Management strategies for the treatment and

prevention of postoperative/postdischarge nausea and vomiting: an updated review. *F1000Res*. 2020;9.

16. Anderson BJ. Paracetamol (Acetaminophen): mechanisms of action. *Paediatr Anaesth*. 2008;18(10):915-21.

17. Essex MN, Xu H, Parsons B, Xie L, Li C. Parecoxib relieves pain and has an opioid-sparing effect following major gastrointestinal surgery. *Int J Gen Med*. 2017;10:319-27.