

Case Report

## Surgical management for a giant hydatid cyst of the lung using Hugon technique

**Authors:**

Khalil Ghebouli<sup>1</sup>, Abdelnacer Haddam<sup>1</sup>, Mohammed Amine Kecir<sup>2</sup>, Mehdi Belbekri<sup>2</sup>, Sedik Merouani<sup>2</sup>, Houda Amrane<sup>2</sup>, Kenza Bendjoudi<sup>3</sup>

*Department of Thoracic Cardiovascular and Organ Transplantation, University Hospital Mustapha, Algiers, Algeria.*

*Department of Thoracic Surgery, University Hospital Ben Badis, Constantine, Algeria.*

*Department of Anesthesia, University Hospital Mustapha, Algiers, Algeria.*

**Corresponding Author:**

Khalil Ghebouli

Article Received: 13-March-2024, Revised: 03-April-2024, Accepted: 23-April-2024

**ABSTRACT:**

Human echinococcosis is a zoonosis caused by Echinococcus Granulosis. It occurs in rural regions where sheep and goat farming is widespread like Algeria. It constitutes a real public health problem. The lung occupies the second location after liver. The management of pulmonary hydatid cyst is essentially surgical. In giant and large pulmonary hydatid cysts, pulmonary resection is the usual method of surgical treatment. We report a case of a patient presenting with a giant hydatid cyst of the lung and treated surgically by Hugon technique which is a conservative technique and consists of enucleation of the cyst.

**Keywords:** *Hydatid cyst of the lung, Cyst enucleation, Surgery*

**INTRODUCTION:**

Pulmonary hydatidosis is cosmopolitan, it occurs in a hyper-endemic in countries where sheep and cattle are raised, like Algeria [1]. This zoonosis represents a serious public health problem and has a significant socio-economic impact. Echinococcus granulosus infection constitutes a significant financial constraint derived from human health costs and animal production losses [2]. The giant hydatid cyst of the lung is a rare entity because the natural evolution of the cyst often leads to complications, especially rupture. . In giant and large pulmonary hydatid cysts, pulmonary resection is the usual method of surgical treatment. In other cases, conservative surgery is the most appropriate method. Several conservative techniques have been described in the literature. These techniques aim to treat the parasite and also the

residual cavity. Among them that described by Hugon in 1952 and which consists of incision in the pulmonary parenchyma and the enucleation of the pulmonary hydatid cyst. We report a case of a patient presenting with a giant hydatid cyst of the lung and treated surgically by Hugon technique.

**CASE REPORT:**

A 26 year old, single lady, from a rural region, presented to our department of thoracic surgery for a management of a giant hydatid cyst of the lung. The circumstances of discovery were marked by respiratory difficulty with right basi thoracic pain. The chest x-ray showed a large right basi thoracic opacity, well limited and with regular contours (Figure 1).

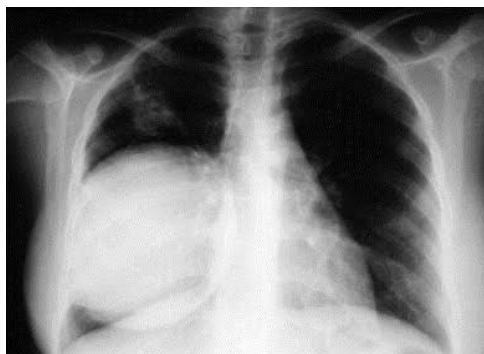
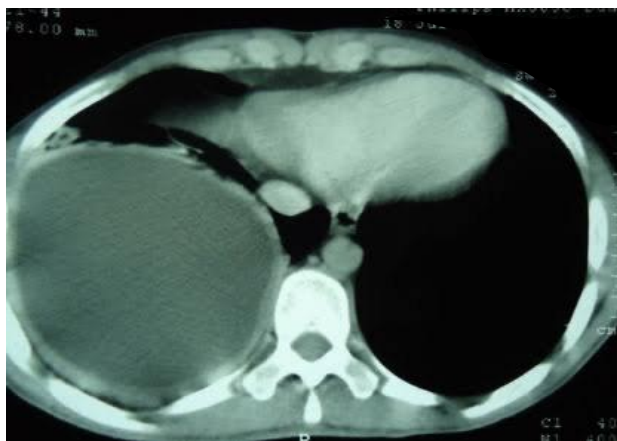

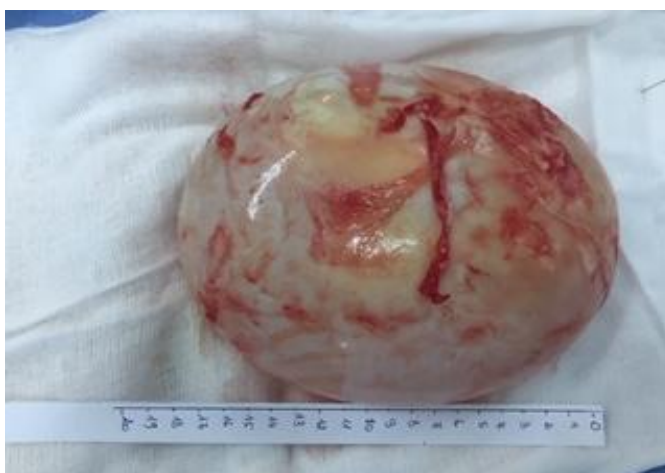Figure 1: Chest x-ray A large right basi thoracic opacity

The chest CT scan showed a round pulmonary image, right basal and water tone of 18cm long axis (Figure 2).



**Figure 2: Chest CT scan A large round right basal pulmonary image**

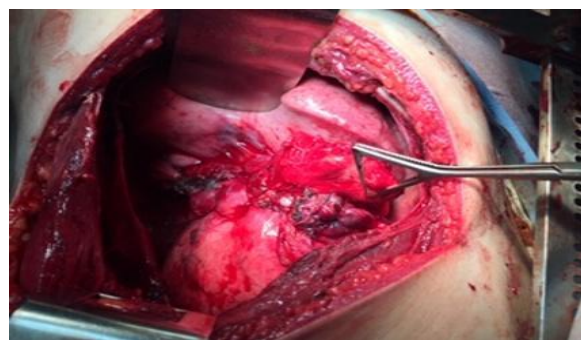
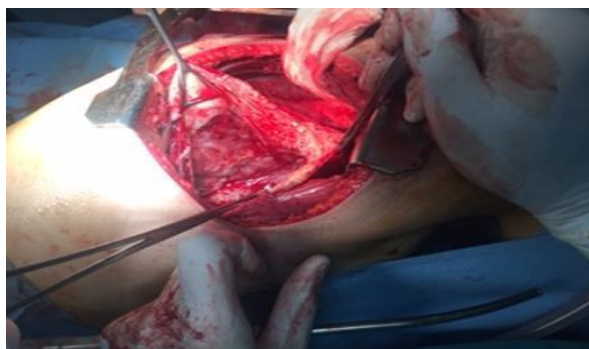Abdominal ultrasound and echocardiography did not show abdominal or pericardial location. Hydatid serology was positive. The patient was operated on under general anesthesia with selective intubation to avoid intraoperative flooding of the contralateral lung. The patient was surgically approached by a right posterolateral thoracotomy passing through the 5th right intercostal space. After total liberation of the lung from cystopleural adhesions, surgical exploration revealed a large right lower lobar pulmonary cystic mass with pleural development. We proceeded to enucleating the cyst (Figure 3). The operating technique consists after incision of the pericyst in delivery of the cyst using a blunt instrument inserted between the cyst and the pericyst or pulmonary insufflation maneuvers performed on request by the anesthetist.



**Figure 3: Enucleation of the cyst (postoperative appearance)**

After enucleation of the cyst. The residual cavity was treated by a subtotal pericystectomy with blinding of the bronchial fistulas using X point (Figure 4a and b).

The surgical procedure was completed by the placement of two chest tubes which were removed on day 2 and day 4. The short and long term evolution was without complication or recurrence. The patient was released from the hospital on day 5 and followed for two years.



**Figure 4: Residual cavity (perioperative appearance) : a before, b after treatment**

## **DISCUSSION:**

Hydatid cyst of the lung is a benign but serious pathology due to its complications, often occurring in young and active people. The pulmonary hydatid increases in the direction of the least resistance and remains spherical as long as it is deep and confronted with homogeneous resistances. Faced with an obstacle, it can become oval, kidney-shaped, pear-shaped. During its evolution, by increasing in volume, the hydatid fluid is under tension. The hydatid, as it develops, comes into contact with the bronchi, erodes their wall and induces the appearance of bronchocystic fistulas at the adventitial level. The size of the cyst varies, from 2 to 10 cm [3], sometimes even larger and can occupy an entire lobe, or even an entire lung [4]. Some authors describe the cyst as giant when it exceeds two thirds of the lung. ipsilateral hemithorax, while others agree on the figure of 10 cm in diameter [5,6] According to Lamy et al. [7], children tend to develop large cysts, probably related to the high elasticity of their lung tissue and the delay in diagnosis due to the delayed onset of symptoms in these young patients. The treatment of hydatid cyst of the lung is essentially surgical and may be as conservative as possible. The surgical procedure is performed under general anesthesia. Ideally, intubation should be selective, allowing, in addition to surgical comfort, to avoid flooding of the contralateral bronchial tree in the event of intraoperative rupture and bronchial obstruction by membrane fragments [8]. In the event of a large cyst exceeding 50% of the lobe, lobectomy is the rule. But the lung parenchyma should be preserved as much as possible, particularly in children and endemic areas, where risk of recurrence is a real concern [9]. Described by Ugon in 1952 and appears to be a simple and elegant technique giving rapid and spectacular results, it consists, after incision of the pericyst, in the enucleation of the cyst using a blunt instrument inserted between the cyst and the pericyst or maneuvers pulmonary insufflation performed on demand by the anesthetist [10]. The existence of the beginning of wilting and a suppurative layer between the cyst and the precyst facilitates the maneuvers. This process eliminates the danger of pleural contamination by the hydatid fluid which often escapes during the puncture, likewise the total enucleation of the cyst reduces the risk of recurrence. On the other hand, and in the event of failure of this technique, the rupture of the cyst leads to contamination of the operating field exposing it to secondary post-operative echinococcosis which it was precisely intended to avoid. This technique is also criticized for the risk of bronchopleural leaks with the possibility of contamination of the residual cavity [11]. Leakage of hydatid fluid after rupture of the cyst intraoperatively or after puncture-evacuation of the cyst remains a major concern for the surgeon because it potentially generates recurrence. However, in a series of 34 cases

of late recurrence, Chevret [12] noted that 29 recurrences involved patients who had undergone an Ugon cystectomy. Qian [13] found a recurrence rate of 3.8% for the enucleation series and 5.6% for the puncture-evacuation series. These findings suggest that there are other factors influencing recidivism. Blinding of bronchial fistulas is systematic. The search for these fistulas is carried out by filling the cavity with physiological serum and asking the anesthesiologist to partially put the excluded lung back into circulation. Any bronchial fistulas are manifested by bubbling in the residual cavity. The bubbling is more important than these fistulas are large. These fistulas must be sutured or stapled carefully; the persistence of a bronchial fistula exposes the risk of prolonged air leak which can lead to reintervention. Several authors agree that it is unnecessary to close the residual cavity after cystectomy or pneumotomy. The idea of leaving the remaining cavity after enucleation was proposed by Allende in 1947 [14]. The flattening technique is inspired by the resection of the protruding dome of the hepatic cyst described by Largot in 1954. After partial pericystectomy and sutures of the bronchial fistulas, the edges of the remaining cavity are treated with everting sutures from the outside towards the inside, thus reducing the cavity and allowing its drainage into the pleural cavity.

## **CONCLUSION:**

Hydatid cyst of the lung is a disease wrongly considered to be benign. However, the results of surgery are very variable because they depend on many factors, in particular the evolutionary stage of the cyst and the operating technique used. In giant and large pulmonary hydatid cysts, pulmonary resection is the rule. But the lung parenchyma should be preserved as much as possible, particularly in children and endemic areas, where risk of recurrence is a real concern. Enucleation of the cyst according to Hugon is a very interesting technique because it avoids recedive but exposes the risk of intraoperative rupture. The technique requires blinding of the fistulas and a pericystectomy in order to avoid the occurrence of complications.

**Conflict of Interest:** None

## **REFERENCES:**

1. Schantz PM (2006) Progress in diagnosis, treatment and elimination of echinococcosis and cysticercosis. *Parasitol Int* 55(Suppl):S7–S13 [Epub 2006 Jan 4]
2. B. Otero-Abad, P. Torgerson A systematic review of the epidemiology of echinococcosis in domestic and wild animals. 2013 Jun 6;7(6):e2249. doi: 10.1371/journal.pntd.0002249.

3. Bouhaouala M.H, Ladeb M.F, Ben Hamouda M. et coll. Radiologie de la maladie hydatique. Feuil. Radiol.1989; 29 (2) : 141-2.
4. Grenier PH. et coll. Imagerie thoracique de l'adulte. Médecine Sciences Flammarion; Paris; 1988.
5. Haddam A-N, Echinococcose kystique pulmonaire. Chirurgie de la cavité adventielle. Thèse 2015.
6. Halezeroglu S, Muharrdm C, Uysal A, Senol C, Keles M, Arman B. Giant hydatid cysts of the lung. J Thorac Cardiovasc Surg 1997; 113:712-7.
7. Kheder A.B, El Mekki L, Hamza M.F. et coll. Les aspects épidémiologiques, cliniques, radiologiques et immunologiques du kyste hydatique pulmonaire en Tunisie
8. Kefi M, Sayed S, HentatiM. et coll. L'anesthésie et la réanimation dans la chirurgie des kystes hydatiques. Tunisie Méd.; 1985; 63 (10) : 559-62.
9. Dakak M, Caylak H, Kavakli K, Gozubuyuk A, Yucel O, Gurkok S, et al. Parenchyma- saving surgical treatment of giant pulmonary hydatid cysts. Thorac Cardiovasc Surg 2009;57(3):165e8.
10. Ugon CV. Therapy of hydatid cysts of the lungs and their complications. J Int Chir 1952;12:155e78.
11. Nabi MS, T. Waseem T. Pulmonary hydatid disease: What is the optimal surgical strategy?International Journal of Surgery 8 (2010) 612e616
12. Chevret R, Jouhari-Ouaraini A, Rahali R. Kystes hydatiques du poumon : problème des récidiives. Chirurgie; 1980; 106 : 673-82.
13. Qian.ZX Thoracic hydatid cysts: a report of 842 cases treated over a thirty year period Ann.Thorac.Surg 1988; 46:342-6
14. Dogan R, Yuksel M, Cetin G. et coll. Surgical treatment of hydatid cysts of the lung (1055 patients). Thorax; 1989; 44 : 192-9.