

## Calcaneo Navicular Coalition in Children Diagnosis and Treatment

Authors:

Pr. DJERBAL Amel\*, Pr. AKLOUL-HAMDAOUI Yousria, Dr. TEBANI Samir, Pr. HARRAR Reda

Specialized Hospital Establishment Salim ZEMIRLI – El Harrach, Algiers, Faculty of Medicine, University of Algiers I  
Trauma and orthopedic surgery, specialist in foot and ankle surgery for children and adults, Specialized hospital establishment Salim  
ZEMIRLI – 16200 El Harrach, Algiers

Corresponding Author:

Pr. DJERBAL Amel

Article Received: 20-November-2023, Revised: 10-December-2023, Accepted: 01-January-2024

### **ABSTRACT:**

Calcaneonavicular coalition (hereafter CN), is an abnormal union between the calcaneus and navicular, which may be bony (complete coalition), cartilaginous (synchondrosis, incomplete coalition) or fibrous (synfibrosis or rudimentary coalition), causing mechanical pain, which usually subside with rest. They occur mainly in the instep area. These pains can be accompanied by repeated sprains, and it is very important to emphasize that repeated sprains in children should strongly suggest the existence of a tarsal coalition, whatever its form. Symptoms most often develop during the second decade of life. Imaging examinations make it possible to diagnose the lesion, its form and its importance for the therapeutic decision. Imaging of synostosis and the CN in children is based on three examinations: standard X-rays and CTscans mainly, with magnetic resonance imaging (MRI) secondarily. Any valgus flatfoot in children should be investigated for synostosis, as in around 40% of cases, synostosis remain asymptomatic. Resection remains the mainstay of treatment, and is a straightforward procedure that regularly gives excellent results, provided that the patient's treatment plan is followed.

**Keywords:** Ankle, Sprains, Fibular contracture, Calcaneo-navicular coalition, Resection

### **INTRODUCTION:**

A calcaneonavicular coalition (hereafter CN) is an abnormal union bridge between the calcaneus and the navicular. This union bridge may be bony (complete coalition), cartilaginous (synchondrosis, incomplete coalition) or fibrous (synfibrosis or rudimentary coalition) [1]. The tarsal coalition has been known since it was described by Buffon in 1769[2] and Cruveilhier in 1829[3]. Between 50% and 60% of tarsal coalitions are CN coalitions. Finally, we must not forget the excessively long antero-medial process of the calcaneus or "calcaneal beak" [4,5], a frustrated form of coalitions which constitutes a clinical entity Fully-fledged..

### **EMBRYOLOGY:**

#### **Two Hypothesis are Reported:**

- The first: CN coalitions result from the incorporation of the secondary calcaneus bone. However, this hypothesis does not explain the genesis of all rudimentary coalitions [2,3].
- The second hypothesis, which is currently the most widely accepted, involves poor organization and segmentation of the

mesenchymal embryos of the foot. Future articulations are formed by the phenomenon of cavitations, with the appearance of primitive articular fissures. If this phenomenon does not proceed normally, an abnormal union bridge remains. This regression defect may affect the navicular in the CN coalition [2,3].

### **WARNING SYMPTOMS:**

Most often develop in the second decade of life, between the ages of 8 and 12 years. The plasticity of the cartilage explains its good tolerance and its radiological transparency is the cause of the impossibility of diagnosis in early childhood. Symptoms only appear with ossification of the interosseous bridges, which generally occurs after the age of eight years [6,7]. Pain, recurrent sprains and foot deformity should be emphasized as the circumstances for diagnosis.

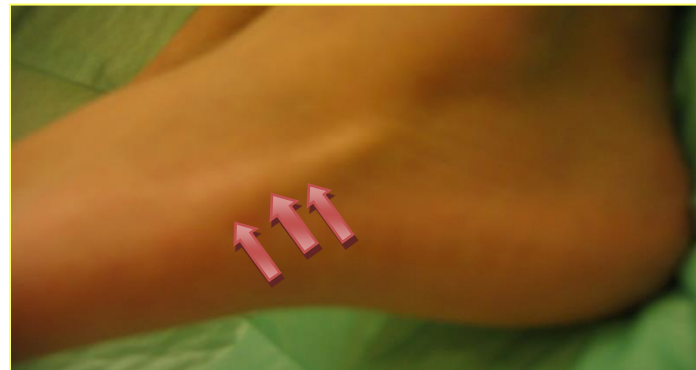### **Pain:**

These are mechanical pains, which appear after prolonged walks, when doing sport or at the end of the day. They usually subside with rest. They occur mainly in the instep area. This pain may be accompanied by

repeated sprains, and it is very important to emphasize that repeated sprains in children should be strongly suggestive of the existence of a tarsal coalition, whatever its form.

**Deformity:**

One of the classic revealing forms of synostosis is contracted flatfoot [8, 9, 10, 11, 12, 13, 14]. This is a foot in which all joint amplitudes are reduced, in which all attempts at mobilisation are painful, and in which the fibular tendons are contracted permanently or in inversion (Figure 1).



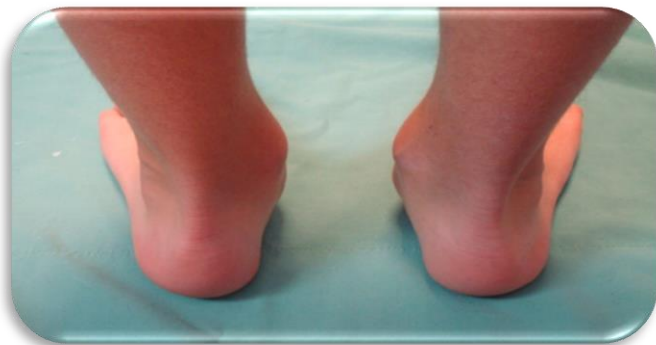**Figure.1 Permanent contracture of the fibular tendons.**

**Source: Orthopedic traumatology department, Specialized hospital establishment Salim ZEMIRLI.**

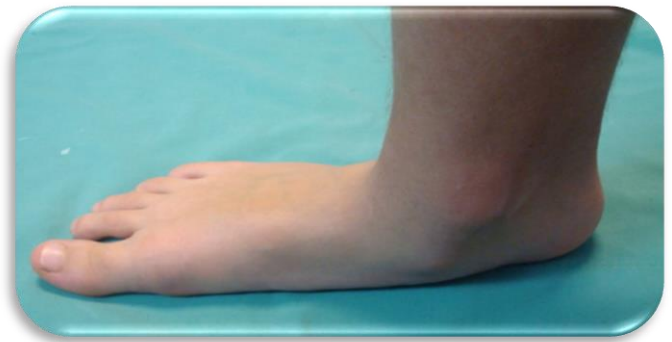A rigid, painful flat foot in a child aged between 10 and 15 years suggests a diagnosis of tarsal coalition before anything else.

**CLINICAL EXAMINATION:**

At the examination, this is typically a severe flat foot with valgus of the hind foot, a significant medial protrusion of the navicular with a break at the medial border (Figure 2, 3). The child should be observed walking from the front and the back in order to assess the flexibility of the foot. When there is synostosis, the arch of the foot does not deepen and the valgus of the hind foot is not corrected (Figure 4).

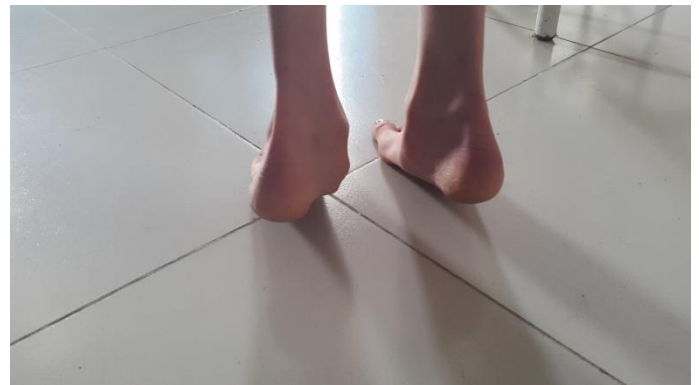

**Figure2. Valgus of the hind foot.**



**Figure 3. A medial protrusion of the navicular.**

**Source: Orthopedic traumatology department, Specialized hospital establishment Salim ZEMIRLI.**



**Figure4. Valgus of the hindfoot cannot be corrected when walking on the toes**

**Source: Orthopedic traumatology department, Specialized hospital establishment Salim ZEMIRLI.**

Pain is reproduced during the examination by forcibly everting the limb while maintaining digital pressure in the tarsal sinus. Joint mobility is then assessed, starting with the tibio-tarsal joint, which may be hyper mobile in a transverse direction [14,15]. The mobility of the subtalar joint is then tested. This examination is often difficult, and an attempt must be made to identify any limitation of mobility between the calcaneus and the navicular. It is necessary to look for fibular contracture. This complete clinical examination of the feet should be supplemented by a neurological and vascular examination of the lower limbs.

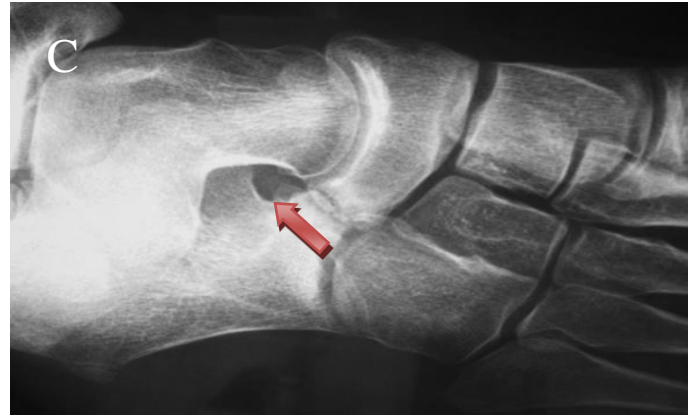At the end of this clinical examination, which is always comparative, it is important to emphasize that the clinical pictures observed can be very different. A synostosis of the tarsus may be discovered during a systematic clinical examination of a foot of normal morphology, asymptomatic but with very limited mobility; the diagnosis is more easily made in the presence of a contracted flat foot in a boy who cannot even walk on his toes because he is in so much pain.

## IMAGING EXAMINATIONS:

Imaging examinations are used to diagnose the lesion, its form and its relevance to the therapeutic indication [16]. Imaging of synostosis and the CN coalition in children is based on three examinations: standard radiography and computed tomography (CT) mainly, with magnetic resonance imaging (MRI) secondarily.

- **X-RAY:**

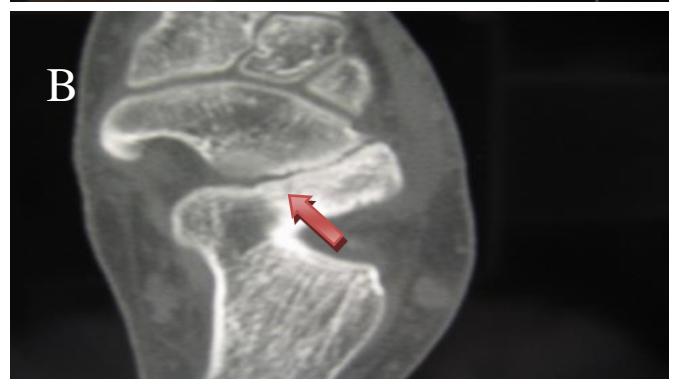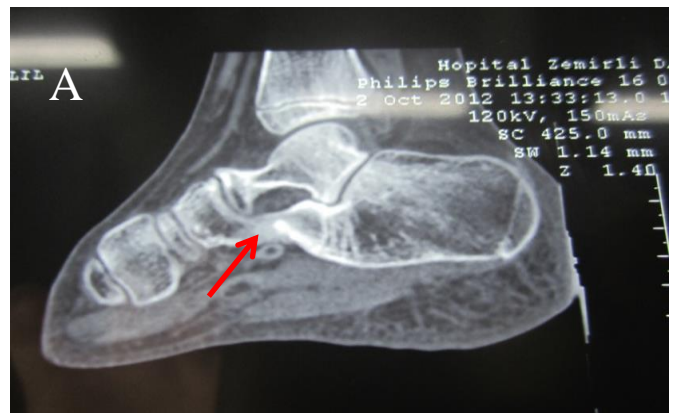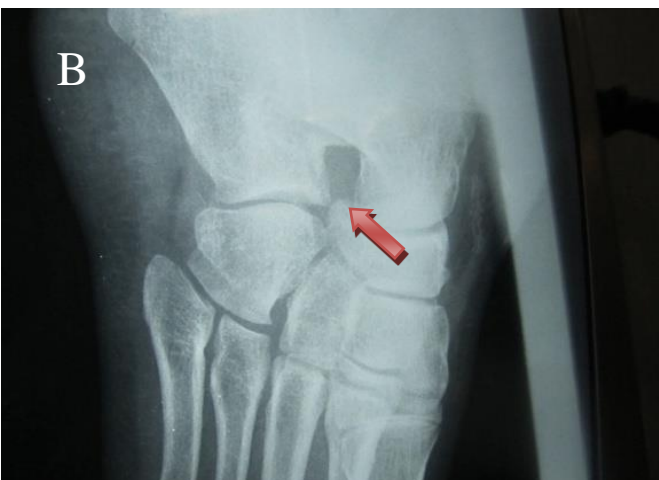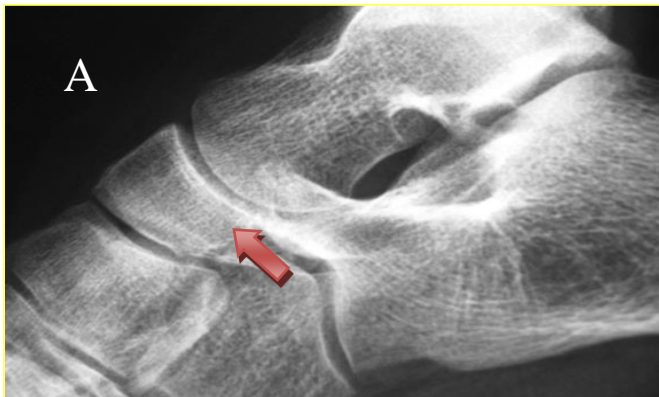X-rays of the foot should be requested, with a lateral and frontal view under stress, combined with a three-quarter internal view of the foot (or unrolled foot). CN synostosis (CNS) is generally diagnosed on these simple standard films, and in particular on three-quarter views. When the CNS is complete, it appears in the form of a bony bridge joining the antero-medial process of the calcaneus process and the medial border of the edge of the navicular bone. When it is incomplete, the diagnosis is more difficult: it is then necessary to look for irregular, condensed bone edges, giving the appearance of a pseudarthrosis (Figure 5). Indirect signs such as hypoplasia of the head of the talus and the appearance of an excessively long anterior process of the calcaneus ("anteater's nose") should be sought.



**Figure5: A: CNS is complete bone. B: CNS is incomplete, C: an excessively long anterior process of the anteater's nose**  
Source: Orthopedic traumatology department, Specialized hospital establishment Salim ZEMIRLI.

- **Computed tomography (CT):**

This is a very useful examination which has completely replaced CT scans and which allows calcaneo-navicular anomalies to be highlighted on horizontal sections (Figure 6). Computed tomography (CT) is used to confirm the diagnosis [17,18].

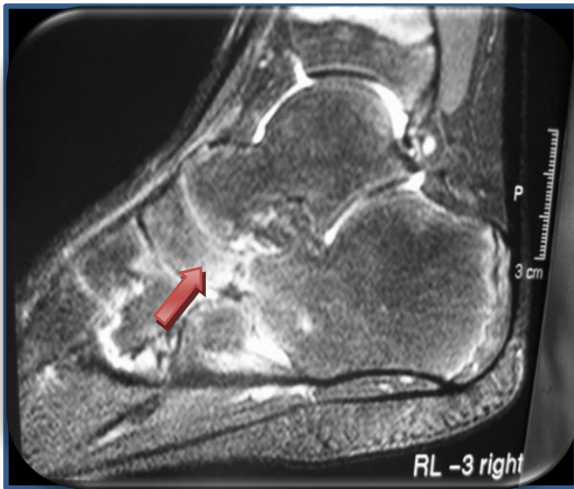

**Figure 6. A: CT scan showing a bony CNS B: CT scan showing a synchondrosis CNS**  
Source: Orthopedic traumatology department, Specialized hospital establishment Salim ZEMIRLI.

The problem remains when synostosis is incomplete or there is synchondrosis, because the nature of the interposition tissue is not perfectly defined by this examination.

- **Magnetic resonance imaging (MRI):**

It is only indicated in very young children when synchondrosis is suspected and the radiographic examination does not show ossification of a bone bridge. It has to be admitted that its interpretation is difficult because, once again, [19,20] the exact nature of the interposition tissue is not always easily identified. (Figure7).



**Figure.7 Fibro-cartilaginous CNS MRI**  
**Source: Orthopedic traumatology department, Specialized hospital establishment Salim ZEMIRLI.**

In practice, imaging examinations are always based on a standard X-ray including a frontal and weight-bearing profile examination of the foot combined with a 3/4 incidence of the foot. As soon as a synostosis is visualized, a search must be made for another synostosis. If there is any doubt, or if surgery is indicated, a CT scan should be ordered [17,19].

**TREATMENT:**

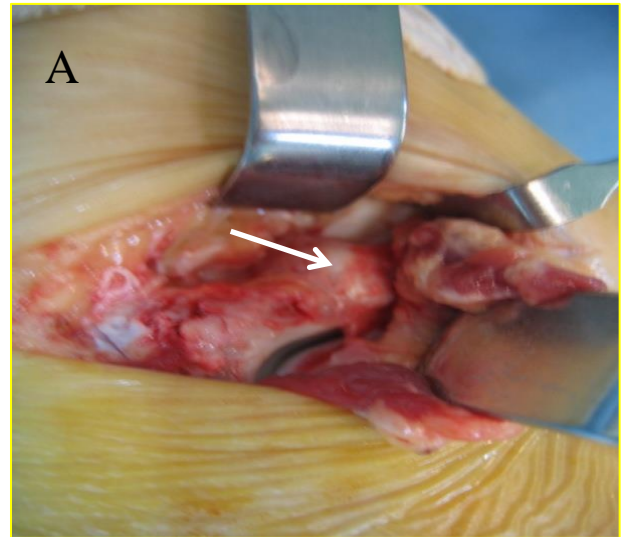
**Conservative Treatment:**

Medical treatments include the use of corrective orthoses, infiltration of the tarsal sinus, immobilisation in a plaster cast (which must be made in inversion), and abstention from surveillance. They are indicated for symptomatic forms of recent discovery in feet with little deformity [21].

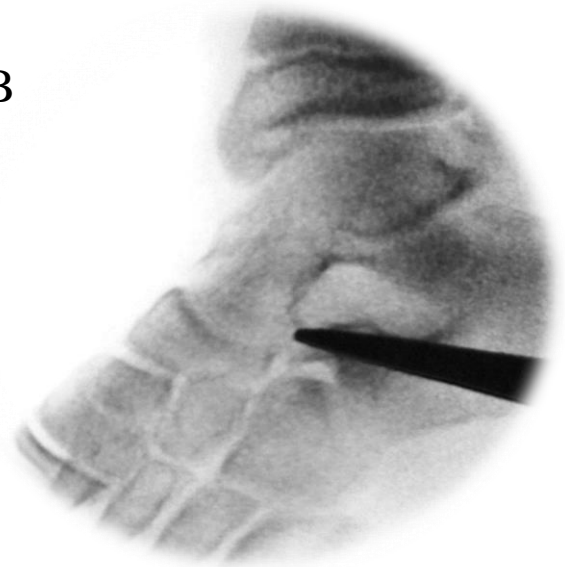
**Surgical Treatment:**

**Includes:**

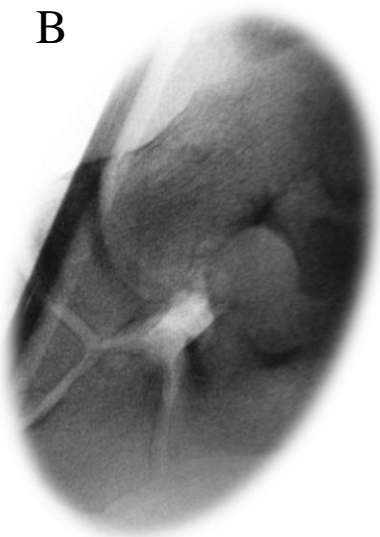
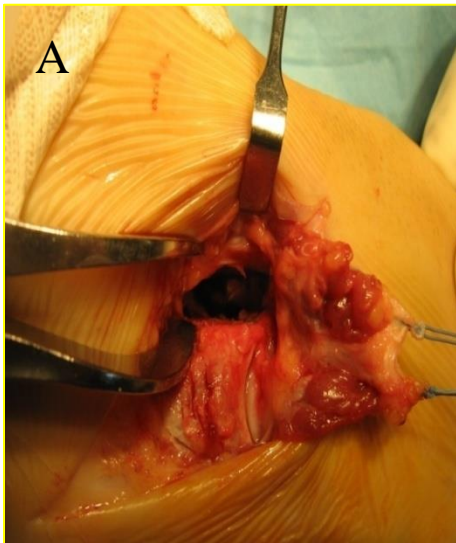
1. Resection of the coalition alone or with interposition of the extensor digitorum brevis (EDB) muscle or fat tissue [22,23,24]. This is a very tempting procedure, as the aim is to restore good mobility to the subtalar and eliminate pain. Resection of the CN coalition has consistently given good and very good results [25,26,27,28,29]. Provided that the resection is sufficient (leaving a CN space greater than or equal to 10mm) (Figure 8, 9).



**B**



**Figure 8. A, B: calcaneo-navicular Bone Bridge intraoperative and radiological**  
**Source: Orthopedic traumatology department, Specialized hospital establishment Salim ZEMIRLI.**



**Figure 9. A : Resection of the CN coalition B:leaving an CN space greater than or equal to 10 mm confirmed at the image intensifier**  
**Source: Orthopedic traumatology department, Specialized hospital establishment Salim ZEMIRLI.**

This procedure provides pain relief, improved mobility and subjective stability. As reported by several authors [30, 31, 32, 33, 34], resection remains the basic surgical treatment for CN synostosis. Early rehabilitation is desirable. To resume weight-bearing, the foot must be well deflated and pain-free.

2. Associated procedures in cases of associated valgus flatfoot:

- lengthening of the calcaneal tendon by vulpius-type aponeurotomy,
- lengthening of the short fibular tendon in its white part,
- Advancement of the posterior tibialis tendon,
- An osteotomy to lengthen the calcaneus.

3. Percutaneous resection of the CN coalition (CNC) was done using a motorized bone burr through a small incision in the sinus tarsi under image intensifier control. After complete resection a synthetic graft of Teflon or Dacron measuring 15 mm ×30 mm was interposed to prevent re-union of the bone bar [35].

4. Although arthroscopic/endoscopic tarsal coalition resection seem to be promising with the possible advantages of faster recovery and reduced local morbidity, this techniques has a long learning curve. Larger case series are needed to definitely confirm the reliability of the arthroscopic/endoscopic procedures and allow a comparison with traditional open techniques [36 37,38, 39].

**CONCLUSION:**

Any valgus flatfoot in children should be investigated for synostosis, as in around 40% of cases synostosis can remain asymptomatic. Imaging examinations make it possible to diagnose the lesion, its form and its importance for the therapeutic decision. Resection remains the gold standard treatment; it is a simple procedure that regularly gives excellent results, provided the indication is rigorous. Arthroscopic resection is a feasible and effective treatment method for symptomatic tarsal coalitions. This relatively new technique results in satisfactory clinical and functional outcomes, with no coalition recurrence reported in the literature. Future studies comparing outcomes of arthroscopy with open tarsal coalition resection are warranted.

**REFERENCES:**

1. D.M. Stormont, H.A. Peterson: The relative incidence of tarsal coalition Clin Orthop Relat Res, 181 (1983), p. 28
2. Buffon G, Conte DE: Histoire naturelle, générale et particulière. With a description of the King's cabinet. Tome 3: 47,1750.
3. Cruveilhier J : Anatomical pathology of the human body 1829. J.B. Baillière, Tome 1.
4. Pouliquen JC, Duranthon LD, Glorion C, Kassis B, Langlais J. The too-long anterior process calcaneus : a report of 39 cases in 25 children and adolescents. J Pediatr Orthop 1998 ; 18 (3) : 333-6.

5. El Hayek T, D'Ollone T, Rubio A, Lusakisimo S, Griffet J. A too-long anterior process of the calcaneus : a report of 31 operated cases. *J Pediatr Orthop B* 2009 ; 18 (4) : 163-6.
6. Clarke D.M. Multiple tarsal coalitions in the same foot. *J Pediatr Orthop* 1997 ; 17 : 777-780.
7. Jay kumar S, Cowell HR: Rigid flatfoot. *Clin Orthop* 1977; 122: 77-84.
8. Cain TJ, Heymann S. Peroneal spastic flatfoot. Its treatment by osteotomy of the calcis. *J Bone Joint Surg (Br)* 1978; 60: 527-529.
9. Cowell HR, Elener V. Rigid painful flatfoot secondary to tarsal coalition. *Clin Ortop*, 1983; 177:54-60.
10. Harris RI, Beath T: Etiology of peroneal spastic flatfoot (rigid valgus foot). *J Bone Joint Surg (Br)* 1948; 30: 624-634.
11. Harris R.I. Retrospect: Peroneal spastic flatfoot ( rigid valgus foot). *J Bone Joint Surg (Am)* 1965; 47: 1657-1667.
12. Mosier K, Asher M. Tarsal coalitions and peroneal spastic flat foot. A review. *J Bone Joint Surg (Am)* 1984; 66: 976-984.
13. M.A. Leonard: The inheritance of tarsal coalition and its relationship to spastic flat foot *J Bone Jt Surg Br*, 56b (3) (1974), p. 520.
14. F. Lemley, G. Berlet, K. Hill, T. Philbin, B. Isaac, T. Lee: Current concepts review: tarsal coalition *Foot Ankle Int*, 27 (12) (2006).
15. Harris B. Anomalous structures in the developing human foot. In: *Anatomical Record*, pp. 399, WILEY-LISS DIV JOHN WILEY & SONS INC, 605 THIRD AVE, NEW YORK, NY 10158-0012. 1955.
16. J.E. Herzenberg, J.L. Goldner, S. Martinez, P.M. Silverman: Computerized tomography of talocalcaneal tarsal coalition: a clinical and anatomic study *Foot Ankle*, 6 (6) (1986), p. 273.
17. C. Pineda, D. Resnick, G. Greenway/ Diagnosis of tarsal coalition with computed tomography, *Clin Orthop Relat Res*, 208 (1986), p. 282.
18. K.M. Nalaboff, M.E. Schweitzer/ MRI of tarsal coalition: frequency, distribution, and innovative signs *Bull NYU Hosp Jt Dis*, 66 (1) (2008), p. 14
19. D.A. Lawrence, M.F. Rolen, A.H. Haims, Z. Zayour, H.A. Moukaddam: Tarsal coalitions: radiographic, CT, and MR imaging findings *HSSJ*, 10 (2) (2014), p. 153
20. F. Birisik, M. Demirel, F. Bilgili, A. Salduz, I. Yeldan, Ismet, *et al*: The natural course of pain in patients with symptomatic tarsal coalitions: A retrospective clinical study, *Foot Ankle Surg*, 26 (2) (2020), p. 228
21. G. Inglis, R.A. Buxton, M.F. Macnicol: Symptomatic calcaneonavicular bars The results 20 years after surgical excision, *J Bone Jt Surg Br*, 68 (1) (1986), p. 128
22. P. Gonzalez, S.J. Kumar : Calcaneonavicular coalition treated by resection and interposition of the extensor digitorum brevis muscle *J Bone Jt Surg Am*, 72 (1) (1990), p.71
23. S.T. Moyes, E.J. Crawford, P.M. Aichroth: The interposition of extensor digitorum brevis in the resection of calcaneonavicular bars *J Pediatr Orthop*, 14 (3) (1994), p. 387
24. Vaughan W.H, Segal G. Tarsal coalition, with special reference to roentgenographic interpretation. *Radiology* 1953; 60: 855-863.
25. McCormack TJ, Olney B, Asher M. Talocalcaneal coalition resection: a 10-year follow-up. *J Pediatr Orthop* 1997; 17: 13-15.
26. Rouvreau Ph, Pouliquen JC, Langlais J, Glorion Ch, De Cerqueira Daltro G. Synostoses and tarsal coalitions in children. Study of 68 cases in 47 patients. *Rev Chir Orthop* 1994; 80: 252-260.
27. E. Andreasen: Calcaneo-navicular coalition. Late results of resection *Acta Orthop Scand*, 39 (3) (1968), p. 424
28. R.B. Chambers, T.M. Cook, H.R. Cowell: Surgical reconstruction for calcaneonavicular coalition. Evaluation of function and gait *J Bone Jt Surg Am*, 64 (6) (1982), p. 829.
29. Khoshbin, M. Bouchard, D. Wasserstein, T. Leroux, P.W. Law, H.J. Kreder, *et al*.: Reoperations after tarsal coalition resection: a population-based study, *J Foot Ankle Surg*, 54 (3) (2015), p. 306
30. S.J. Mubarak, P.N. Patel, V.V. Upasani, M. A. Moor, D.R. Wenger: Calcaneonavicular

- coalition: treatment by excision and fat graft, *J Pedia Orthop*, 29 (5) (2009), p. 418
31. Dutoit M, Rigault P, Padovani JP, Pouliquen JC, Finidori G, Touzet Ph, Guyonvarch G. *Rev Chir Orthop* 1984; 70: 231-243.
  32. Roger AJ, Méary R. Congenital synostosis of the tarsal bones. About 41 cases. *Rev Chir Orthop* 1969; 55: 721-741.
  33. Tachdjian M.O. *Pediatric orthopedics*. Philadelphia. W.B. Saunders, 1988; 2578-2611.
  34. A.T. Scott, H.R. Tuten: Calcaneonavicular coalition resection with extensor digitorum brevis interposition in adults, *Foot Ankle Int*, 28 (8) (2007), p. 890
  35. Percutaneous resection of calcaneonavicular coalition with interposition of synthetic graft. El Shazly O, Abou El Ela AA. *Foot (Edinb)* 2011;21:138–141.
  36. Endoscopic coalition resection. Bonasia DE, Phisitkul P, Amendola A. *Foot Ankle Clin*. 2015; 20:81–91.
  37. E. FaubelNavarrete, M. Sánchez-González, V. Vicent, E. Puchol :Endoscopic resection of the calcaneonavicular coalition *Rev Esp Cir Ortop Trauma*, 64 (6) (2020), p. 375
  38. T.J. Jackson, S.E. Mathew, A.N. Larson, A. A. Stans, T.A. Milbrandt: Characteristics and reoperation rates of paediatric tarsal coalitions: a population-based study, *J Child'S Orthop*, 14 (6) (2020), p. 537
  39. A.H. Nehme, J. BouMonsef, A.G. BouGhanam, J.P. Imad, R. Moucharafieh, J. Wehbe: Arthroscopic resection of a bilateral calcaneonavicular coalition in a child *J Foot Ankle Surg*, 55 (5) (2016), p. 1079.