

## A rare case of pneumonia caused by *Achromobacter Denitrificans* concomitant with pulmonary embolism after gastrectomy for gastric cancer

**Correspondence Author :** 1 Wenjing Wang, 2 Ganzhu Feng, 3 Sabreen Abdul Rahman

National Natural Science Foundation of China 81870009.

Email : [athena\\_wang1980@126.com](mailto:athena_wang1980@126.com) , [zhu1635253@163.com](mailto:zhu1635253@163.com).

---

### CASE REPORT

The patient was a 77-year-old female rural farmer. On Oct/5/2017, the patient was admitted due to "upper abdominal pain for about 20 days". After six days, the patient received radical total gastrectomy. Post operative pathological diagnosis: gastric cardia adenocarcinoma stage II B (T3N1M0). Chest CT (30/09/2017) showed normal in two lungs before this operation. On the sixth day after the operation, an emergency laparotomy was performed because of postoperative abdominal bleeding. After that, the patient was

shivering accompanied by a large amount of sputum in the mouth, a slow coughing reflex, and desaturation to lower than 90%. The patient was hence switched to ICU for advanced treatment. A chest X-ray (Oct/24/2017) showed increased bilateral lung markings and some bit of bilateral pleural effusion. On Nov/1/2017, she was discharged on her improvement. After that, the patient began to suffer from not only cough and expectoration but also chest tightness. On Nov/19/2017 the patient was admitted again. Three days later, the patient

began to have a fever. The white blood cell count was  $14.8 \times 10^9/L$  with 79.9% neutrophils. Blood gas analysis demonstrated  $PaO_2$  69mmHg,  $PaCO_2$  30mmHg (oxygen intaking 3L/min). D-Dimer was 2.53ug/ml. The results of endotoxin were 1.49EU/ml. The G test and GM tests detected three times were basically normal.

Cefodizime and moxifloxacin were used together first. Computed tomographic pulmonary angiography (CTPA) (Nov/21/2017, Figure 1a) showed bilateral pulmonary embolism, multiple left lung lesions with the possibility of bronchiectasis or mycotic infection. Then the patient was treated by intra-arterial thrombolysis in his left pulmonary artery. Deep venous thrombosis of the lower extremities was not found. Pulmonary thrombus still partially remained after treatment, and enoxaparin and warfarin were continued. However, cough, expectoration and dyspnea did not improve. The chest CT (Dec/01/2017, Figure 1b) showed that the left lung multiple

lesions were larger than before. Considering the possibility of MRSA or aspergillus infections, the anti-infection protocol was adjusted to teicoplanin combined with voriconazole. Re-examination of CTPA (Dec/7/2017, Figure 1c) showed bilateral pulmonary embolism improved with progressive left lung multiple cavity lesions.

Since Dec/8/2017, *Achromobacter denitrificans* (*A. denitrificans*) were detected from sputum cultures four different times. On Dec/9/2017, bronchoalveolar lavage was performed. Then the samples were cultured for *A. denitrificans* and diluted Amikacin 0.2g was injected locally. On Dec/11/2017, meropenem was used for two weeks and piperacillin /tazobactam for the following two weeks. Seven days later, fever, cough, expectoration and dyspnea gradually improved. Chest CT (Dec/16/2017, Figure 1d) showed a significant reduction in the focus of infection.

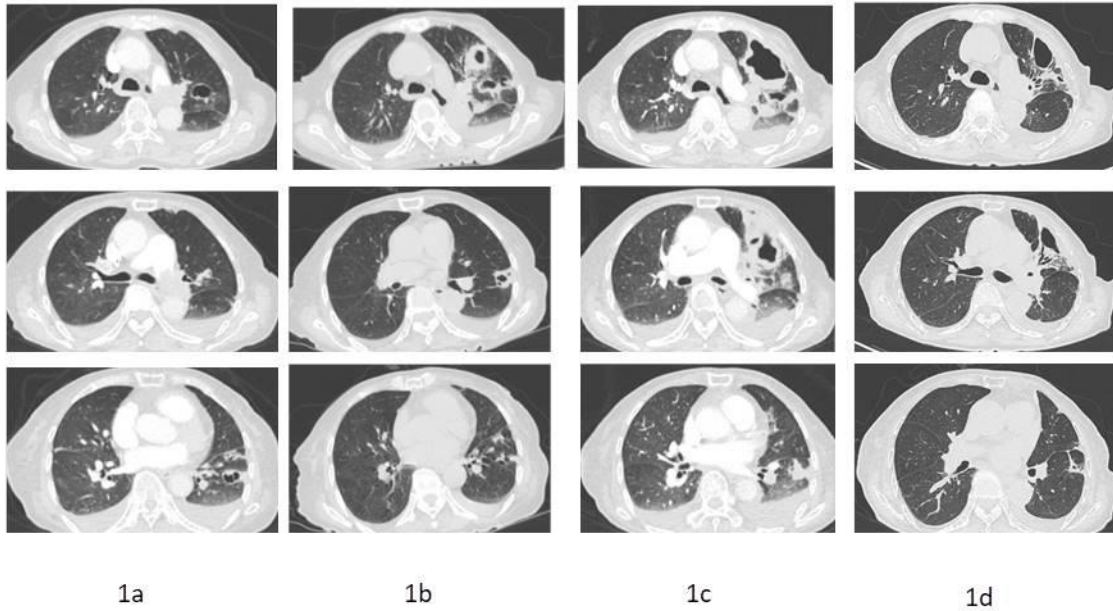


Figure 1 Chest CT of the patient

## DISCUSSION

Studies have shown that the incidence of hospital-acquired pneumonia secondary to abdominal surgery is as high as 10.7%, with a mortality rate of 19-65%. It is related to the decline of the whole respiratory system function due to the effect of pain at surgical wound site on the chest and the diaphragm movement leading to the decrease of lung capacity; decreased excretion of airway mucus; malnutrition; decline in local and systemic immunity; the invasive operation

and the use of antibiotics providing more adequate conditions for growth and reproduction of pathogenic bacteria. Therefore, more than half of the postoperative complications can be reduced in patients with abdominal surgery with early respiratory and systemic system rehabilitation training; early off-bed activity and active nutritional support<sup>(6)</sup>.

There are two specials in this case of post operative pulmonary infection as follows:

### **1. Infectious disease with specific pathogenic bacteria**

*A. denitrificans* is a species that belongs to the genus *Achromobacter*. It is a Gram-negative, mobile, strictly aerobic, ubiquitous bacterium not fermenting glucose, oxidase and catalase-positive. It inhabits soil, human skin, digestive tract and aquatic environments (including well water, intravenous fluids and water in humidifiers)<sup>[2,3]</sup>. It is an opportunistic pathogenic bacterium causing bloodstream infection, respiratory tract infection, urinary tract infection, endocarditis and intraperitoneal infection, etc., especially in malignant tumors, and in patients with immunodeficiency and invasive medical procedures. This bacterium's ubiquity can lead to hospital-acquired infections or even epidemics<sup>[4]</sup>.

There are relatively more reports about respiratory infections caused by *Achromobacter* catalase-positive. However, there are few records about the pulmonary infection of *A. denitrificans*. At present, its characteristic pathogenicity is not very clear. So far, five cases of extrapulmonary infection have been reported; including renal abscess<sup>[5]</sup>, prosthetic valve endocarditis (PVE)<sup>[6,7]</sup>, meningitis, and intraperitoneal dialysis catheter infection<sup>[8]</sup>. In the only two cases caused by *A. denitrificans*, those two patients had underlying lung diseases in the past, one case due to lung destroy secondary to pulmonary tuberculosis<sup>[4]</sup>, and another case accompanied by asthma and bronchiectasis<sup>[9]</sup>. Here, the patient had no previous history of structural underlying lung diseases, so it was the first report of a case without underlying lung disease of *A. denitrificans* pneumonia. Pneumonia in this patient may be related to radical gastrectomy. After the second operation, the patient experienced shivering with a large amount of sputum in

the mouth and slow cough reflex, accompanied by significant desaturation and a great probability of aspiration. The patient had a history of gastric cancer. After two operations, the patient suffered from malnutrition, a significantly decreased respiratory and systemic immunity, all of which are high risks of pneumonia.

*A. denitrificans* is resistant to many kinds of antimicrobials. In this case the drug sensitivity test suggests that it is resistant to ampicillin/sulbactam, cefazolin, cefotetan, ceftriaxone, aztreonam, ciprofloxacin, levofloxacin and tobramycin, intermediate to cefepime and gentamicin while sensitive to amikacin, ceftazidime, imipenem, trimethoprim/sulfamethoxazole and piperacillin/tazobactam. Before the etiology of the disease has been found, the patient was given moxifloxacin, cefodizime, teicoplanin and voriconazole which were ineffective. Then *A. denitrificans* was cultured and the disease was basically cured after two weeks use of meropenem

and piperacillin/tazobactam. So far, there has been no specific guideline or recommendation for an anti-infective regimen. In the previous case reports, antimicrobials were selected according to the site of infection and drug sensitivity. The course of treatment was varied between 2 to 8 weeks, such as renal abscess administered with meropenem for 60 days to cure<sup>[5]</sup>, endocarditis with imipenem for 6 weeks to cure<sup>[6]</sup>, and another case of endocarditis first with meropenem and trimethoprim/sulfamethoxazole and then subsequent with levofloxacin for 4 weeks in all<sup>[7]</sup>. For meningitis, meropenem was used for 15 days to cure<sup>[10]</sup>. For catheter-related infection, ciprofloxacin was used for 2 weeks to cure<sup>[8]</sup>. One case of pneumonia used meropenem for 2 weeks<sup>[4]</sup>, and another case of pneumonia used levofloxacin for 6 weeks<sup>[9]</sup>. In conclusion, early identification of etiology and selection of drugs based on drug sensitivity plays a crucial role in the overall prognosis.

Previously reports showed that *Achromobacter xylosoxidans* can produce emphysema, lung structural damage, recurrent pulmonary infection<sup>[11]</sup>; and can readily form biofilm, strong motility, strong drug resistance, as well as colonization in patients with structural lung disease<sup>[12]</sup>, but the prognosis of *A. denitrificans* has not yet been reported. In this case multiple pulmonary cavities have already formed. After treatment, the lesions were fewer. We will follow up for a long time.

## **2. Special pneumonia accompanied by pulmonary embolism.**

VTE (venous thromboembolism) is one of the most important complications of the tumor. Its incidence is 4%~20%<sup>[13]</sup>, and it is also one of the causes leading to death. VTE includes deep venous thrombosis (DVT) and pulmonary thromboembolism (PTE). The risk in cancer patients is several times higher than that of non-tumor patients. Hospitalized bed-ridden patients with tumors are high-risk groups of VTE.

Evidence-based medicine has found that the risk of thrombosis in patients with cancer is increased by 4~6 times<sup>[13]</sup>. Hypercoagulation, compression of tumor on the vessel and bed-ridden status are high-risk factors of thrombosis in malignant tumor patients. Without anticoagulants administered postoperatively, tumor patients are prone to PTE as high as 4%~10% and the mortality is 1%~5%. According to autopsy results, the incidence of PTE in gastric cancer patients was 16%. It was suggested to prescribe perioperative prophylactic anticoagulation<sup>[13]</sup>. However, failed thrombolysis may be related to the delayed treatment. In this case, there was no evidence of distant metastasis of gastric cancer.

Whether there is a correlation between pulmonary embolism and *A. denitrificans* pulmonary infection has not been mentioned in previous reports. However, a case was mentioned of thrombophlebitis complicated with osteomyelitis after

traumatic *Achromobacter xylosoxidans*<sup>[4]</sup>. It is still unclear whether or not the correlation exists. The possibility of bacterial thrombus was reduced without positive blood culture results. Further study is required to determine if *A. denitrificans* easily promote thrombosis and if gastric cancer is a main cause of pulmonary embolisms.

## References:

[1] Boden I, Skinner EH, Browning L, *et al.* Preoperative physiotherapy for the prevention of respiratory complications after upper abdominal surgery: pragmatic, double blinded, multicentre randomised controlled trial[J]. *BMJ (Clinical research ed)*.2018,360:j5916.

[2] Glupczynski Y, Hansen W, Freney J, *et al.* In vitro susceptibility of *Alcaligenes denitrificans* subsp. *xylosoxidans* to 24 antimicrobial agents[J]. *Antimicrobial agents and chemotherapy*.1988,32(2):276-8.

[3] Coenye T, Vancanneyt M, Falsen E, *et al.* *Achromobacter insolitus* sp. nov. and *Achromobacter spanius* sp. nov., from human clinical samples[J]. *International journal of systematic and evolutionary microbiology*.2003,53(Pt 6):1819-24.

[4] Aundhakar S, Mane M, Bharadiya A, *et al.* "Watch out! Pneumonia secondary to *achromobacter denitrificans*"[J]. *Annals of medical and health sciences research*.2014,4(Suppl 1):S22-4.

[5] Sgrelli A, Mencacci A, Fiorio M, *et al.* *Achromobacter denitrificans* renal abscess[J]. *The new microbiologica*.2012,35(2):245-7.

[6] Derber C, Elam K, Forbes BA, *et al.* *Achromobacter* species endocarditis: A case report and literature review[J]. *The Canadian journal of infectious diseases & medical microbiology = Journal canadien des maladies infectieuses et de la microbiologie medicale*.2011,22(3):e17-20.

[7] Padmaja K, Lakshmi V, Amaresh M, *et al.* Prosthetic Valve Endocarditis with aortic root abscess[J]. *International Journal of Infection Control*.2013,9(1).

[8] Cankaya E, Keles M, Gulcan E, *et al.* A rare cause of peritoneal dialysis-related peritonitis: *Achromobacter denitrificans*[J]. *Peritoneal dialysis international : journal of the International Society for Peritoneal Dialysis*.2014,34(1):135-7.

[9] Awadh H, Mansour M, Aqtash O, *et al.* Pneumonia due to a Rare Pathogen: *Achromobacter xylosoxidans*, Subspecies *denitrificans*.2017,2017:3969682.

- [10] Manckoundia P, Mazen E, Coste AS, *et al.* A case of meningitis due to *Achromobacter xylosoxidans* denitrificans 60 years after a cranial trauma[J]. *Medical science monitor : international medical journal of experimental and clinical research*.2011,17(6):Cs63-5. reports.2015,2015.
- [11] Duggan JM, Goldstein SJ, Chenoweth CE, *et al.* *Achromobacter xylosoxidans* bacteremia: report of four cases and review of the literature[J]. *Clinical infectious diseases : an official publication of the Infectious Diseases Society of America*.1996,23(3):569-76.
- [12] Trancassini M, Iebba V, Citera N, *et al.* Outbreak of *Achromobacter xylosoxidans* in an Italian Cystic fibrosis center: genome variability, biofilm production, antibiotic resistance, and motility in isolated strains[J]. *Frontiers in microbiology*.2014,5:138.
- [13] Jun Ma, Yilong Wu, Shukui Qin, *et al.* Guidelines on prevention and treatment of tumor-associated venous thromboembolism in China (Version 2015)[J]. *Chinese Journal of Practical Internal Medicine*.2015(11):907-20.
- [14] Pamuk G, Aygun D, Barut K, *et al.* *Achromobacter* causing a thrombophlebitis and osteomyelitis combination: a rare cause[J]. *BMJ case*