

Microscopic needles in a painful elbow swelling -A case report of Atypical Gout

Authors:

Dr. Monica Mishra¹, Dr. Gunvanti Rathod², Dr. Deepankar Satapathy³, Dr. Alisha Khan⁴

¹Senior Resident, Pathology and Lab Medicine department, AIIMS, Bibinagar

²Additional Professor, Pathology and Lab Medicine department, AIIMS, Bibinagar

³Associate Professor, Department of Orthopaedics, AIIMS, Bibinagar

⁴Junior Resident, Pathology and Lab Medicine department, AIIMS, Bibinagar

Corresponding Author:

Dr. Monica Mishra

<https://doi.org/10.5281/zenodo.15181955>

Article Received: 27-February-2025, Revised: 18-March-2025, Accepted: 08-April-2025

ABSTRACT:

A nodular subcutaneous swelling at elbow in an elderly patient should raise suspicion of infection or malignancy. A 63 year male patient presented with painful swelling in right elbow which was present for two years. It was insidious in onset and gradually increased to the present size. Clinical examination revealed a 6x5x5cm soft swelling, compressible, non-reducible, tender and overlying skin was pinch able. The uric acid level was 8.3mg/dl which was within normal limit. Patient complained that pain worsened on intake of alcohol and used to subside upon medication. The main clinical differential diagnosis were bursitis and gouty arthritis. On histopathological examination it revealed Gouty arthritis after ruling out granulomatous inflammation, foreign body giant cell reaction.

Keywords: Gouty arthritis, uric acid, elbow, histopathology

INTRODUCTION:

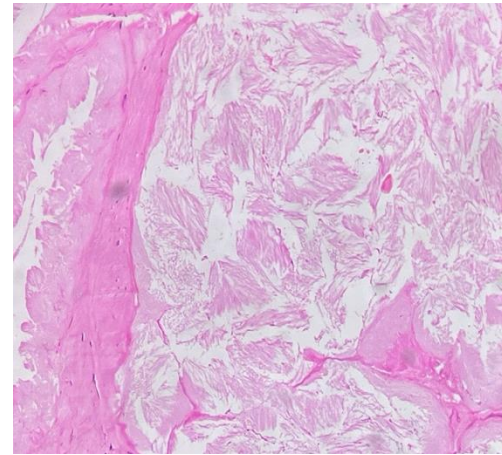
A nodular subcutaneous swelling in an elderly patient should raise suspicion of infection or malignancy. It becomes difficult to diagnose a case accurately with only clinical findings. Histopathology is the confirmatory for any nodular swellings at elbow region. Gouty arthritis of the elbow is relatively uncommon, occurring in about 2–5% of cases of gout, as gout more frequently affects the lower extremities. It is caused by the deposition of monosodium urate crystals in the synovial fluid and periarticular tissues due to hyperuricemia. Histopathologically, gout shows needle-shaped urate crystals under polarized light, surrounded by inflammatory cells like neutrophils and macrophages. Chronic cases may display tophi, characterized by dense urate deposits encased in fibrotic tissue with chronic inflammatory infiltration. On histopathology many differential diagnosis have to consider e.g. granulomatous inflammation, foreign body giant cell reaction, crystal induced arthritis(1) We report a case of old aged patient who presented with painful elbow swelling and normal urate level which required a histopathological examination for final diagnosis.

CASE REPORT:

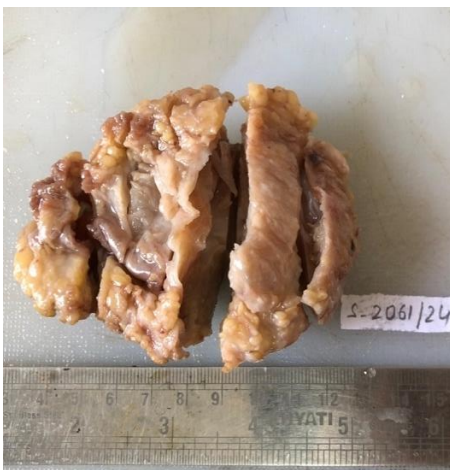A 63 year male patient presented with painful swelling in right elbow which was present for two years. It was insidious in onset and gradually increased to the present size. Clinical examination revealed a 6x5x5cm soft swelling, compressible, tender, non-reducible and overlying skin was pinchable. The patient is not having any symptoms and risk factors suggestive of gout like chronic kidney disease, metabolic syndrome. The uric acid level was 8.3mg/dl which was within normal limit. Patient complained that pain worsened on intake of alcohol and used to subside upon medication. The main clinical differential diagnosis were bursitis and gouty arthritis. We received a skin covered elliptical tissue specimen which was measuring 8.8x6.4x3cm. On serial slicing nodular whitish calcified area noted. (Photograph 1,2) On histopathological examination there were nodular aggregates of needle like acellular, amorphous eosinophilic material surrounded by foamy histiocytes and multinucleated giant cells. The intervening area showed inflammatory infiltrate and thin walled blood vessels. There was absence of granuloma and atypia. (Photograph 3,4,5) Final diagnosis was given as Gouty arthritis after ruling out various differential diagnosis.



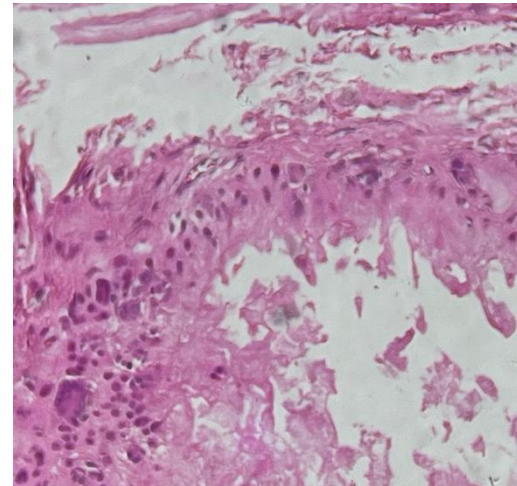
Photograph 1 showed skin covered soft tissue swelling



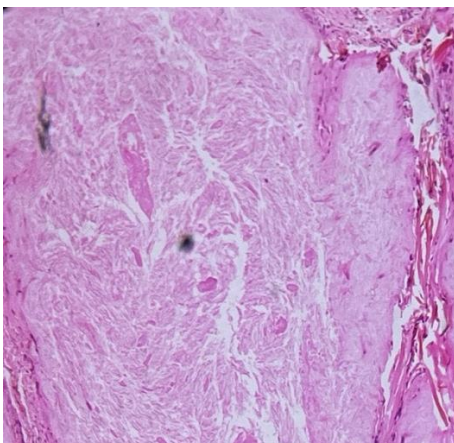
Photograph 4 showed needle shaped crystals(10x, H&E stain)



Photograph 2 showed cut surface with whitish calcified area



Photograph 5 showed multinucleate giant cells and peripheral palisading of histiocytes (40x, H&E stain)



Photograph 3 showed nodular aggregate of needle shaped urate crystals (4x, H&E stain)

DISCUSSION:

Gout is a form of inflammatory arthritis primarily caused by the deposition of monosodium urate (MSU) crystals in joints and surrounding tissues.(2) These crystals can deposit in various tissues, particularly in the synovial fluid of joints, and trigger an inflammatory response. The crystals are recognized by the innate immune system, especially by macrophages, which phagocytose the crystals and release pro-inflammatory cytokines, such as interleukin-1 β (IL-1 β). This results in the characteristic symptoms of gout e.g. severe pain, swelling, and redness, often in the first metatarsophalangeal joint but also in other joints and soft tissues.(2)

Histologically, the hallmark of gout is the presence of MSU crystals within the tissue, which can be also be detected using polarized light microscopy. However, recent research has expanded our understanding of the

tissue response to these crystals, highlighting the intricate interplay between MSU crystals and various immune cells, including macrophages, neutrophils, and T lymphocytes.(2)The classic histopathological feature of gout is the presence of needle-shaped MSU crystals, which can be identified in tissue specimens obtained from synovial fluid, tophi, or excised tissues. The crystals exhibit strong birefringence under polarized light, making them easily distinguishable from other types of crystals, such as calcium pyrophosphate dihydrate (CPPD) crystals. Tophi, the visible deposits of urate crystals, are a common histopathological feature in chronic gout. These tophi are composed of large aggregates of MSU crystals surrounded by a granulomatous inflammatory reaction. The crystals in tophi are often surrounded by a fibrous capsule and may lead to significant joint destruction over time. The cellular infiltrate around tophi is typically composed of macrophages, multinucleated giant cells, and lymphocytes, with evidence of chronic inflammation and fibrosis.(1)In the acute phase of gout, synovial tissues exhibit a characteristic inflammatory response to MSU crystals. Histologically, this is marked by synovial hyperplasia, with increased synoviocyte proliferation and infiltration of neutrophils, macrophages, and lymphocytes. These cells release various pro-inflammatory cytokines, such as IL-1 β and tumor necrosis factor-alpha (TNF- α), which further amplify the inflammatory response.(3)In chronic gout, the inflammatory infiltrate in the synovium is more persistent, with a shift toward a more organized chronic inflammatory reaction. Synovial lining cells may undergo hyperplasia, and the synovial membrane may thicken. Moreover, the long-term presence of MSU crystals leads to the formation of pannus, a tissue that invades and erodes the articular cartilage and subchondral bone, contributing to joint damage and deformity.

Recent studies have improved our understanding of how MSU crystals initiate and sustain inflammation within the joint microenvironment. One key advancement has been the recognition of the inflammasome pathway in gout. MSU crystals activate the NLRP3 inflammasome, a complex of proteins that play a pivotal role in the innate immune response. Activation of the inflammasome triggers the maturation and release of IL-1 β , which is a central mediator of the inflammatory cascade in gout. Understanding the role of the inflammasome has led to the development of targeted therapies, such as IL-1 inhibitors, which have shown promise in managing acute gout attacks.(2) Furthermore, research has highlighted the role of the synovial macrophage in gout pathology. Macrophages not only phagocytose MSU crystals but also release various cytokines and chemokines that recruit other immune cells to the site of inflammation. The integration of histopathological findings with clinical and molecular insights has improved the diagnosis and management of gout.

Advances in imaging techniques, such as dual-energy CT (DECT) and ultrasound, now allow for non-invasive visualization of urate crystal deposits, complementing histopathological analysis. These tools are particularly useful in diagnosing gout in patients who do not present with overt symptoms or who have atypical presentations.(2)(4)(5) However, histopathological examination is the gold standard for final diagnosis.

CONCLUSION:

Recent advances in the histopathology of gout have provided new insights into the mechanisms of disease progression, from the deposition of MSU crystals to the complex inflammatory processes that lead to joint damage. Understanding the role of the inflammasome, macrophage polarization, and synovial inflammation has not only enhanced diagnostic approaches but also paved the way for novel therapeutic strategies. As research continues, further advancements in histopathological techniques and molecular biology are expected to refine our understanding of gout and improve outcomes for patients suffering from this debilitating condition

REFERENCES:

1. Omar F, Nor Hashimah AMM, Suhaila AW, Mohammad Mohaidin F, Raymond AA. Atypical gouty tophus masquerading as a foreign body granuloma. *Egypt J Intern Med.* 2024 Aug 5;36(1):79.
2. Ahmad MI, Masood S, Furlanetto DM, Nicolaou S. Urate Crystals; Beyond Joints. *Front Med.* 2021 Jun 4;8:649505.
3. Kiefer D, Erkenberg J, Braun J. Similarities and differences between gouty arthritis and rheumatoid arthritis—an interesting case with a short look into the literature. *Explor Musculoskelet Dis.* 2023 Feb 24;11–9.
4. Hammer HB, Rollefstad S, Semb AG, Jensen G, Karoliussen LF, Terslev L, et al. Urate crystal deposition is associated with inflammatory markers and carotid artery pathology in patients with intercritical gout: results from the NOR-Gout study. *RMD Open.* 2022 Jul;8(2):e002348.
5. Ragab G, Elshahaly M, Bardin T. Gout: An old disease in new perspective – A review. *J Adv Res.* 2017 Sep;8(5):495–511.